

Imprinted H19 oncofetal RNA is a candidate tumour marker for hepatocellular carcinoma

I Ariel, H-Q Miao, X-R Ji, T Schneider, D Roll, N de Groot, A Hochberg, S Ayesch

Abstract

Aims/Background—To study the expression of the H19 gene in hepatocellular carcinoma. H19 is an imprinted, maternally expressed gene, which is tightly linked, both physically and functionally, to the paternally expressed insulin-like growth factor 2 (IGF II). IGF II is known to be involved in liver carcinogenesis. H19 was first discovered in the fetal mouse liver to be under the same regulatory genes as α fetoprotein (α FP), a widely used tumour marker for hepatocellular carcinoma.

Methods—Using both radioactive and non-radioactive in situ hybridisation, the expression of the H19 gene was compared with the presence of α FP, as demonstrated by immunohistochemistry, in 18 cases of hepatocellular carcinoma.

Results—H19 expression was present in 13 of 18 cases, whereas staining for α FP was positive in only nine of 18 cases. Concordance was found in 12 of 18 tumours (66.7%). In general, the staining pattern for H19 was more diffuse than the immunohistochemical staining for α FP.

Conclusions—The addition of a non-radioactive in situ hybridisation assay for H19 RNA to the panel of tumour markers used for the histopathological and cytological diagnosis of hepatocellular carcinoma might be useful.

(*J Clin Pathol: Mol Pathol* 1998;51:21-25)

Keywords: hepatocellular carcinoma; H19; α fetoprotein

Imprinted genes—genes that are expressed from only one allele, depending on the parental origin—are implicated in playing an important role in the tumorigenesis of certain human neoplasms.¹⁻⁴ To date, the H19 gene is one of the few genes proved to be imprinted in humans.^{5,6} Although it has been suggested by other investigators that H19 acts as a tumour suppressor gene,⁷ we have shown that it exhibits oncofetal characteristics, and is re-expressed in tumours arising from tissues that express the gene in fetal life.⁸⁻¹¹ One of the organs that expresses H19 abundantly from the early stages of embryogenesis is the liver.^{12,13} Expression is confined to hepatocytes and mesenchymal tissues, and is undetectable in haemopoietic tissue, one of the main tissue components in the developing liver.^{10,13} H19 expression is downregulated in most adult tissues, including the liver, but may reappear in the liver during regeneration.¹⁴ We were the first to document H19 expression in hepatocellular carcinoma.¹⁰

This observation was confirmed recently by Li *et al*, who found parallel expression of H19 and insulin-like growth factor 2 (IGF II).¹⁵

H19 is one of the few genes that functions as RNA molecules,¹⁶ similar to Xist,¹⁷ the imprinted gene in the Prader-Willi syndrome region¹⁸ and the 3' untranslated region of α tropomyosin.¹⁹ In these cases, a protein product does not exist, and gene expression can, therefore, be determined only by the presence of RNA transcripts in the tissue. We performed radioactive and non-radioactive in situ hybridisation (ISH) for H19 RNA on paraffin wax sections of 18 hepatocellular carcinomas and examined its expression in both the tumour and adjacent liver tissue (when present in the section).

Alpha fetoprotein (α FP) is a widely used tumour marker in hepatocellular carcinoma.^{20,21} The expression of α FP mRNA in mice is determined by at least two transacting genes, raf and Rif. The former determines the basal levels of α FP, while the latter induces its expression during regeneration.¹⁴ The H19 gene was first characterised as a locus unlinked to α FP, which is also regulated by raf and Rif in the liver, but not in other tissues.¹⁴

We examined the presence of α FP by immunohistochemical staining, and correlated our findings with the expression of H19 in these samples. We found that H19 expression is concordant with the presence or absence of α FP in the tumour in two thirds of the cases, and the ISH for H19 was found to be positive in more cases, although the difference was not found to be significant in this small series. We suggest that ISH for H19 RNA should be examined further, as this molecule might be a useful additional tumour marker for the histopathological and cytological diagnosis of hepatocellular carcinoma.

Methods and materials

SAMPLES

Paraffin wax blocks of 18 patients with hepatocellular carcinoma from the department of pathology, Qingdao University School of Medicine in Qingdao, China were submitted for the study. The medical charts were searched for clinical and laboratory data including tumour size, serum α FP, and hepatitis B serum antigen (HBsAg).

We performed radioactive and non-radioactive ISH studies for H19 RNA and an immunohistochemical study for α FP according to the following protocols.

PREPARATION OF H19 TRANSCRIPTION VECTOR

Human H19 gene (800 base pairs) was subcloned at EcoRI site into Bluescript II KS

Department of Pathology, Perinatal Pathology and Quantitative Molecular Pathology Unit, Hadassah University Hospital Mount Scopus, PO Box 24035, il-91240 Jerusalem, Israel
I Ariel
D Roll

Department of Biological Chemistry, Institute for Life Sciences, Hebrew University of Jerusalem, Jerusalem, Israel
T Schneider
N de Groot
A Hochberg
S Ayesch

Department of Oncology, Tumor Biology Research Unit, Hadassah University Hospital, Kiryat Hadassah, Jerusalem, Israel
H-Q Miao

Department of Pathology, Qingdao University School of Medicine, Qingdao, China
X-R Ji

Correspondence to:
Dr Ariel.
email: ariel@hadassah.org.il

Accepted for publication
4 December 1997

Table 1 Clinical data of 18 patients with hepatocellular carcinoma and the results of the *in situ* hybridisation for H19 RNA and immunohistochemistry for a fetoprotein

Case	Sex	Age	Tumour size	HBsAg	saFP	aFP	H19
1	M	47	Multicentric	+	+	+ f	+ d
2	NA	NA	NA	NA	NA	+ f	+ d
3	M	49	Biopsy	-	-	+ d	+ d
4	M	63	Multicentric	+	+	+ f	+ d
5	F	44	Multicentric	+	-	-	+ f
6	F	64	4 × 4 × 4 cm	+	-	-	+ f
7	NA	NA	NA	NA	NA	+ f	+ d
8	M	45	Multicentric	+	+	-	-
9	M	59	10 × 10 × 10 cm	+	+	-	-
10	F	48	Multicentric	+	+	-	+ f
11	F	49	10 × 10 × 10 cm	+	+	+ d	-
12	M	55	Multicentric	-	-	-	+ f
13	M	41	Multicentric	+	+	+ d	+ d
14	M	67	Multicentric	-	+	-	+ f
15	M	40	9 × 8 × 6 cm	+	+	+ d	+ d
16	M	63	7 × 7 × 7 cm	+	+	-	-
17	M	52	22 × 14 × 8 cm	-	-	+ d	+ d
18	M	49	7 × 7 × 7 cm	+	+	-	-

HBsAg, hepatitis B surface antigen; saFP, serum α fetoprotein; f, focal; d, diffuse; NA, data not available.

plasmid (Stratagene) behind the T7 and T3 RNA polymerase binding sites. *In vitro* RNA transcription with T7 RNA polymerase was used to produce antisense H19 cRNA from linearised plasmid DNA. Sense H19 RNA prepared with T3 polymerase was used for control.

PREPARATION OF RIBOPROBE FOR RADIOACTIVE IN SITU HYBRIDISATION

³⁵S-labelled *in vitro* RNA transcripts (10⁷ cpm/ μ g) were produced using the Amersham RPN 2006 Kit and RNA polymerases from Boehringer Mannheim (Mannheim, Germany). Linearised plasmids were prepared by digestion with HindIII (antisense) and EcoRI (sense). The fragments were separated from unincorporated nucleotides by ethanolic precipitation.

RADIOACTIVE IN SITU HYBRIDISATION

The procedure was performed on paraffin wax sections as described in detail previously.¹⁰ The slides were examined and photographed using an Axioplan 2 (Carl Zeiss Jena GmbH, Göttingen, Germany) microscope under bright and dark field illumination.

The negative controls in this study included hybridisation with sense RNA probe and RNase prehybridisation treatment. Negligible signal was observed in all the controls. Positive controls consisted of sections of fetal renal and liver tissue.

PREPARATION OF RIBOPROBE FOR

NON-RADIOACTIVE IN SITU HYBRIDISATION

Digoxigenin labelled *in vitro* RNA transcripts were produced by labelling with DIG-11-UTP by SP6, T3, or T7 RNA polymerase in an *in vitro* transcription reaction (Boehringer Mannheim).

NON-RADIOACTIVE IN SITU HYBRIDISATION

Sections were prepared as for radioactive ISH, and were rehydrated through a series of alcohols, followed by a wash in 0.9% NaCl and then a wash in phosphate buffered saline (PBS). Basic proteins were removed by incubation in 0.1 N HCl at room temperature for 15 minutes. After a further wash in distilled water, sections were treated with 10 μ g/ml proteinase K (Sigma, Poole, Dorset, UK) in 50 mM Tris, 5 mM EDTA for 30 minutes at 37°C, rinsed in PBS, and then refixed for five minutes in 4% paraformaldehyde/PBS. Thereafter, the sections were rinsed in PBS and acetylated for 10 minutes in fresh acetic anhydride diluted 1/400 in 0.1 M triethanolamine (Sigma) at pH 8.0. The slides were then rinsed in PBS for five

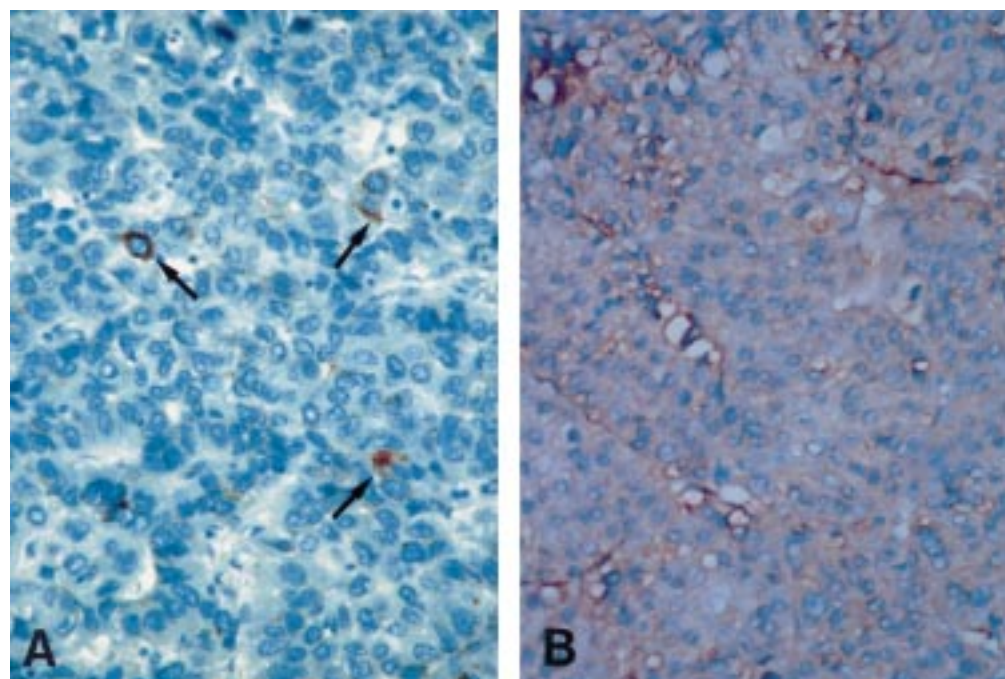


Figure 1 (A) Immunohistochemical staining for a fetoprotein in hepatocellular carcinoma. Positive staining is present in single tumour cells (arrows). (B) H19 expression in the same tumour, as demonstrated by digoxigenin labelled *in situ* hybridisation. Expression is evident in most tumour cells.

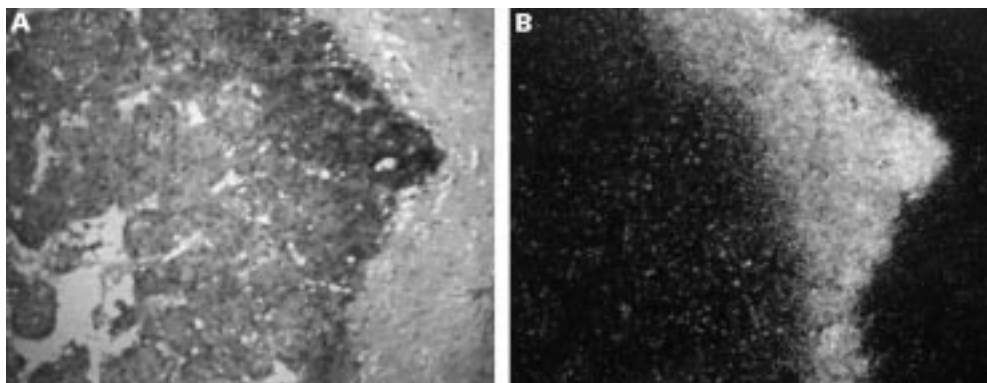


Figure 2 H19 expression in hepatocellular carcinoma. (A) Bright and (B) dark field. The expression is most prominent at the boundary of the tumour nodule. (In situ hybridisation of ^{35}S -labelled antisense of H19 with haematoxylin and eosin as a counterstain.)

minutes and in 0.9% NaCl for another five minutes, dehydrated, and air dried.

The hybridisation buffer contained 50% deionised formamide, 0.3 M NaCl, 20 mM Tris-HCl (pH 7.4), 5 mM EDTA, 10 mM NaH_2PO_4 (pH 8.0), 10% dextran sulphate, 1 \times Denhardt's solution, and 0.5 $\mu\text{g}/\text{ml}$ yeast tRNA. Each section was covered with 30 μl of the hybridisation solution containing 30–100 ng of DIG labelled RNA probe. The sections were covered with siliconised coverslips. Hybridisation was performed at 48–52°C for at least 16 hours in a humid chamber. After hybridisation, coverslips were gently floated off in 5 \times saline sodium citrate (SSC) at 50°C for 30 minutes. Subsequently, tissues were subjected to a stringent wash at 60°C in 50% deionised formamide, 2 \times SSC for 20 minutes.

After a double rinse for 10 minutes in washing buffer (0.4 M NaCl, 10 mM Tris-HCl, and 5 mM EDTA), treatment with RNase A (20 $\mu\text{g}/\text{ml}$) was performed for 30 minutes at 37°C. The sections were rinsed again for five minutes in washing buffer, then washed in 2 \times SSC, 0.5 \times SSC, and 0.1 \times SSC at 37°C. The sections were equilibrated in buffer 1 (100 mM Tris-HCl and 150 mM NaCl, pH 7.5) at room temperature. The sections were then incubated in whole sheep's serum diluted 1/50 for 30 minutes (to avoid non-specific crossreactions of the primary antibody). Incubation with the antidigoxigenin antibody (Boehringer) diluted 1/1000 in buffer 1 was performed for two hours at room temperature. After two washes in buffer 1, the sections were equilibrated in buffer 2 (100 mM Tris-HCl, 100 mM NaCl, and 50 mM MgCl_2 , pH 9.5) for two minutes and incubated with a freshly prepared colour substrate solution containing nitroblue tetrazolium salt (340 $\mu\text{g}/\text{ml}$), 5-bromo-4-chloro-3-indolyl, phosphate toluidine salt (170 $\mu\text{g}/\text{ml}$), and levamisole (1 mM) in buffer 2. The slides were placed in a humid chamber and allowed to develop in the dark for 12–14 hours at room temperature. The reaction was stopped in buffer 3 (10 mM Tris-HCl and 1 mM EDTA, pH 7.4) for a few minutes. Finally, the sections were counterstained with 3% Giemsa stain, quickly dehydrated, and mounted in Entellan.

Controls for the specificity of the ISH included as follows: RNase A pretreatment of the sections; hybridisation with a sense RNA

probe; and hybridisation with hybridisation buffer without the probe. A section of fetal kidney, which expresses H19 in the metanephric blastema, was used as a positive control.

IMMUNOHISTOCHEMISTRY

A polyclonal rabbit primary antibody was used for histochemical detection of αFP on paraffin wax sections (DPC ImmunoStain, Los Angeles, California, USA). Visualisation of αFP in the sections was made by the streptavidin-biotin immunoperoxidase technique using Histostain SP Kit (Zymed Lab Inc, San Francisco, California, USA) according to the manufacturer's directions.

Results

The clinical and laboratory data are presented in table 1.

Expression of H19 was detected by ISH in 13 of 18 samples with hepatocellular carcinoma. Expression was found to be prominent and diffuse in eight of 13 positive samples (fig 8), and weak or prominent and focal (in less than one third of the tumour) in the remaining five samples (table 1). In six cases, we noted a gradual increase in the amount of expression in the malignant hepatocytes at the boundary of the tumour nodules (fig 2). The results of the radioactive and the newly developed non-radioactive studies were found to be essentially identical.

Immunohistochemical staining for αFP was found to be positive in nine of 18 samples. Of those, it was present only focally in single cells throughout the tumour in four cases (fig 1), and in a relatively large number of cells in the remaining five positive tumours (table 1).

Non-neoplastic liver tissue was present in 14 of 18 sections and in all but one section this non-neoplastic tissue was negative for H19 expression. In the one positive sample, prominent expression of H19 was noted in the nodules of cirrhotic liver, whereas no expression was detected in the tumour itself. It is of interest to note that this sample was from an HBsAg positive patient. The remaining eight samples from HBsAg positive patients that included non-neoplastic liver tissue in the histological section were negative for H19 in the cirrhotic liver tissue.

Table 2 Comparison of staining for H19 RNA by ISH and for α FP by immunohistochemistry

	H19+	H19-
α FP+	8	1
α FP-	5	4

When the expression of H19 (by ISH) was compared with immunohistochemical staining for α FP, concordance was found in 12 of 18 cases: in eight samples, both were found to be positive and in four samples, both were negative. In the remaining six cases, the results were discordant: in five samples, the H19 gene was expressed and α FP was not present, and in one sample, H19 expression was not detected but α FP was found to be positive (table 2).

Discussion

Despite extensive research for more than a decade, the biological role of the H19 gene is still not understood. A clue might lie in its tight linkage with the gene for IGF II. The latter is a member of a family of growth factors and their receptors that play an important role in cell proliferation and differentiation.²² The H19 and IGF II genes are reciprocally imprinted and their expression is linked in fetal and adult tissues.^{12 23-25} The relation between their allelic status and abundance of expression has been investigated in certain types of human cancer.^{1 3 15 26-30} The two genes reside close to each other on chromosome 11p15.5, and it has been shown in mice that they share a common enhancer.³¹

IGF II is one of the growth factors known to be involved in liver carcinogenesis in humans and animal models.^{4 15 22 32-38} It regulates tissue specific gene expression in rat and human hepatomas, and this effect seems to be dependent on the degree of tumour differentiation.²² In the experimental model of woodchuck liver carcinogenesis, IGF II blocks apoptosis induced by N-myc.^{36 37} Loss of heterozygosity in SV40 Tag induced murine hepatocellular carcinoma was demonstrated in one third of the tumours with partial or complete loss of maternal chromosome 7 (the mouse syntenic gene of the human chromosome 11), which resulted in overexpression of IGF II and suppression of H19 expression.³⁹ Although the allelic status of H19 was not the subject of our study, it appears from our findings of H19 expression in 13 of 18 tumours, that this is not the case in human hepatocellular carcinoma. In fact, a deletion at 11p13-14, not at the region of IGF II/H19, was found to be induced by hepatitis B virus (HBV) in hepatocellular carcinoma in humans.⁴⁰ It was also found that IGF II expression in human hepatomas is upregulated by HBV at the post-transcriptional level.

Another gene known to be co-expressed with H19 in the liver (in mice) is α FP.¹⁴ α FP is a glycoprotein synthesised by the fetal liver and yolk sac. Hepatic synthesis is reduced markedly after birth: newborn serum contains a highly variable concentration of between 10 and 200 mg/l but by 8 months of age, concentrations have reached the adult level of less than 20 mg/l.⁴¹ Raised concentrations of serum α FP are seen both in benign (mainly hepatic) and malignant diseases, and it is widely used as a tumour marker for the diagnosis and follow up of liver cancer.^{20 21} Of the liver tumours, hepatocellular carcinoma is often associated with a remarkable increase of serum α FP and a

raised serum α FP concentration is always present in another liver tumour, hepatoblastoma. High serum α FP is also found frequently in germ cell tumours with a yolk sac component. Occasionally, raised concentrations of α FP are seen in other types of cancer, predominantly tumours originating in the gastrointestinal tract. Adenocarcinomas with hepatoid differentiation, present among pancreatic, lung, and renal cancer, seem to be associated consistently with raised serum α FP. It should be mentioned, however, that many other gastrointestinal carcinomas present with raised serum α FP as well as positive immunohistochemical staining of tumour cells.⁴¹

The final diagnosis of hepatocellular carcinoma is made by histopathological examination of biopsy material. The diagnosis is based on morphology and is assisted by a panel of special stains and immunohistochemistry.⁴² The differential diagnosis includes primary cholangiocarcinoma and metastatic carcinoma. Further difficulty may arise in differentiating atypical regenerating hepatocytes in liver cirrhosis from hepatocellular carcinoma in cores of needle biopsies.

When immunohistochemical staining for α FP is performed, a weak staining is often seen, although this was not our experience in the present study. Difficulty in the interpretation of this weak staining is probably the reason for the wide range of positive staining for α FP documented in the literature.⁴² Moreover, α FP may also be detected in non-neoplastic hepatocytes by the immunohistochemical method.⁴¹ When comparing the immunohistochemical staining of α FP in our series to the expression of the H19 gene as demonstrated by ISH, the latter method gave a more diffuse staining pattern (fig 1) and was positive in more cases (table 2), although the difference was not statistically significant ($p = 0.29$, using Fisher's exact test). The use of the ISH technique for diagnosis in routine laboratories of pathology has become possible as a result of the development of commercial kits for non-radioactive ISH. The procedure is only slightly more complicated than immunohistochemistry. We intend to study more cases of hepatocellular carcinoma in order to assess the possible value of H19 as a tumour marker.

Recently, the diagnosis of hepatocellular carcinoma in fine needle aspirates has been introduced.^{43 44} The cytological findings are assisted by various immunohistochemical stains, including α FP. Staining for α FP was found to be positive in only 44% of the cases and was present focally in single cells in the fine needle aspirates.⁴³ We have recently developed a method for detection of H19 expressing cells in cytological specimens, such as urine (unpublished data). It is possible that ISH for H19 expression, taking into account the more diffuse and uniform pattern in tissue sections, may prove to be useful for the diagnosis of hepatocellular carcinoma in fine needle aspirates.

We suggest that further work should be carried out to investigate the use of H19 as a candidate tumour marker to be applied to

histological and cytological preparations, along with other special stains and immunohistochemistry, for the diagnosis of hepatocellular carcinoma.

This work was supported by the Trilateral Grant (Germany-Israel-Palestinian Authority) from the DFG, Germany, Grant No. 1490 by the DKFZ, Heidelberg, Germany and Grant No. 95.00163 from the US-Israel Binational Science Foundation.

- 1 Feinberg AP. Genomic imprinting and gene activation in cancer. *Nat Genet* 1993;4:110-13.
- 2 Hochberg A, Gonik B, Goshen R, et al. A growing relationship between genomic imprinting and tumorigenesis. *Cancer Genet Cytogenet* 1994;73:82-3.
- 3 Tycko B. Genomic imprinting: mechanism and role in human pathology. *Am J Pathol* 1994;144:431-43.
- 4 De Souza AT, Yamada T, Mills JJ, et al. Imprinted genes in liver carcinogenesis. *FASEB J* 1997;11:60-7.
- 5 Rachmilewitz J, Goshen R, Ariel I, et al. Parental imprinting of the human H19 gene. *FEBS Lett* 1992;309:25-8.
- 6 Zhang Y, Tycko B. Monoallelic expression of the human H19 gene. *Nat Genet* 1992;1:40-4.
- 7 Hao Y, Crenshaw M, Moulton T, et al. Tumour-suppressor activity of H19 RNA. *Nature* 1993;365:764-7.
- 8 Ariel I, Lustig O, Oyer CE, et al. Relaxation of imprinting in trophoblastic disease. *Gynecol Oncol* 1994;53:212-19.
- 9 Ariel I, Lustig O, Schneider T, et al. The imprinted H19 as a tumor marker in bladder carcinoma. *Urology* 1995;45:335-8.
- 10 Ariel I, Ayes S, Perlman EJ, et al. The product of the imprinted H19 gene is an oncofetal RNA. *J Clin Pathol: Mol Pathol* 1997;50:34-44.
- 11 Biran H, Ariel I, de Groot N, et al. Human imprinted genes as oncodevelopmental markers. *Tumor Biol* 1994;15:123-34.
- 12 Goshen R, Rachmilewitz J, Schneider T, et al. The expression of the human H19 and IGF2 genes during human embryogenesis and placental development. *Mol Reprod Dev* 1993;34:374-9.
- 13 Lustig O, Ariel I, Ilan J, et al. Expression of the imprinted H19 gene in the human fetus. *Mol Reprod Dev* 1994;38:239-46.
- 14 Pachnis V, Belagew A, Tilghman SM. Locus unlinked to α -fetoprotein under the control of the murine raf and Rif genes. *Proc Natl Acad Sci USA* 1984;84:5523-7.
- 15 Li X, Nong Z, Ekstrom C, et al. Disrupted IGF2 promoter control by silencing of promoter P1 in human hepatocellular carcinoma. *Cancer Res* 1997;57:2048-54.
- 16 Brannan CI, Dees EC, Ingram RS, et al. The product of the H19 gene may function as an RNA. *Mol Cell Biol* 1990;10:28-36.
- 17 Brockdorf N, Ashworth A, Kay GF, et al. The product of the mouse Xist gene is a 15 kb inactive X specific transcript containing no conserved ORF and located in the nucleus. *Cell* 1992;71:515-26.
- 18 Wevrick R, Kerns JA, Francke U. Identification of a novel paternally expressed gene in the Prader-Willi syndrome region. *Hum Mol Genet* 1994;3:1877-82.
- 19 Rastinejad F, Conboy MJ, Rando TA, et al. Tumor suppression by RNA from the 3' untranslated region of α -tropomyosin. *Cell* 1993;75:1107-17.
- 20 Abelev GI. Alpha-fetoprotein: 25 years of study. *Tumor Biol* 1989;10:63-74.
- 21 Tatarinov YS. The past and the future for cancer testing by alpha-fetoprotein. A review. *J Nucl Med Allied Sci* 1989;33(suppl 3):5-11.
- 22 Zvibel I, Brill S, Reid LM. Insulin-like growth factor II regulation of gene expression in rat and human hepatomas. *J Cell Physiol* 1995;162:36-43.
- 23 Voutilainen R, Ilvesmaki V, Ariel I, et al. Parallel regulation of parentally imprinted H19 and insulin-like growth factor-II genes in cultured human fetal adrenal cells. *Endocrinology* 1994;134:2051-6.
- 24 Ariel I, Weinstein D, Voutilainen R, et al. Genomic imprinting and the endometrial cycle. the expression of the imprinted gene H19 in the human female reproductive organs. *Diagn Mol Pathol* 1997;6:17-25.
- 25 Eversole-Cire P, Fergusson-Smith AC, Surani AM, et al. Coordinate regulation of Igf-2 and H19 in cultured cells. *Cell Growth Diff* 1995;6:337-45.
- 26 Elkin M, Shevelev A, Schulze E, et al. The expression of the imprinted H19 and IGF-2 genes in human bladder carcinoma. *FEBS Lett* 1995;374:57-61.
- 27 Kondo M, Suzuki H, Ueda R, et al. Frequent loss of imprinting of the H19 gene is often associated with its overexpression in human lung cancers. *Oncogene* 1995;10:1193-8.
- 28 Taniguchi T, Sullivan MJ, Ogawa O, et al. Epigenetic changes encompassing the IGF2/H19 locus associated with relaxation of IGF2 imprinting and silencing of H19 in Wilms' tumor. *Proc Natl Acad Sci USA* 1994;92:2159-63.
- 29 Van Gurp RJLM, Oosterhuis JW, Kalscheuer V, et al. Human testicular germ cell tumors show biallelic expression of the H19 and IGF2 gene. *J Natl Cancer Inst* 1994;86:1070-5.
- 30 Yballe CM, Vu TH, Hoffman AR. Imprinting and expression of insulin-like growth factor-II and H19 in normal breast tissue and breast tumor. *J Clin Endocrinol Metab* 1996;81:1607-12.
- 31 Leighton PA, Ingram RS, Eggenschwiler J, et al. Disruption of imprinting caused by deletion of the H19 region in mice. *Nature* 1995;375:34-9.
- 32 Cariani E, Lasserre C, Kemeny F, et al. Differential expression of insulin-like growth factor II mRNA in human primary liver cancer, benign liver tumors and liver cirrhosis. *Cancer Res* 1988;48:6844-9.
- 33 d'Arville CN, Nouri-Aria KT, Johnson P, et al. Regulation of insulin-like growth factor II gene expression by hepatitis B virus in hepatocellular carcinoma. *Hepatology* 1991;13:310-15.
- 34 Fiorentino M, Grigioni WF, Baccarini P, et al. Different in situ expression of insulin-like growth factor type II in hepatocellular carcinoma. An in situ hybridization and immunohistochemical study. *Diagn Mol Pathol* 1994;3:59-65.
- 35 Su Q, Liu YF, Zhang JF, et al. Expression of insulin-like growth factor II in hepatitis B, cirrhosis and hepatocellular carcinoma: its relationship with hepatitis B antigen expression. *Hepatology* 1994;20:788-99.
- 36 Ueda K, Ganem D. Apoptosis is induced by N-myc expression in hepatocytes, a frequent event in hepadnavirus oncogenesis, and is blocked by insulin-like growth factor II. *J Virol* 1996;70:1375-83.
- 37 Yang D, Faris R, Hixon D, et al. Insulin-like growth factor II blocks apoptosis of N-myc2-expressing woodchuck liver epithelial cells. *J Virol* 1996;70:6260-8.
- 38 Tabor E. Tumor suppressor genes, growth factor genes, and oncogenes in hepatitis B virus-associated hepatocellular carcinoma. *J Med Virol* 1994;42:357-65.
- 39 Casola S, Ungaro P, Padone PV, et al. Loss of heterozygosity of imprinted genes in SV/40 tT antigen induced hepatocellular carcinoma. *Oncogene* 1995;11:711-21.
- 40 Rogler CE, Sherman M, Su CY, et al. Deletion in chromosome 11p associated with a hepatitis B integration site in hepatocellular carcinoma. *Science* 1985;230:319-22.
- 41 Christiansen M, Ishiguro T, Hogdall C, et al. Alpha-fetoprotein. In: Ballesta AM, et al, eds. *Updating on tumor markers in tissues and biological fluids*. Torino: Edizioni Minerva Medica, 1993:245-69.
- 42 Hurlimann J, Gardiol D. Immunohistochemistry in the differential diagnosis of liver carcinomas. *Am J Surg Pathol* 1991;15:280-8.
- 43 Guindi M, Yazdi HM, Gilliatt MA. Fine needle aspiration biopsy of hepatocellular carcinoma. Value of immunohistochemical and ultrastructural studies. *Acta Cytol* 1994;38:385-91.
- 44 Wee A, Nilsson B, Tan LK, et al. Fine needle aspiration biopsy of hepatocellular carcinoma. Diagnostic dilemma at the ends of the spectrum. *Acta Cytol* 1994;38:347-54.



Imprinted H19 oncofetal RNA is a candidate tumour marker for hepatocellular carcinoma.

I Ariel, H Q Miao, X R Ji, et al.

Mol Path 1998 51: 21-25
doi: 10.1136/mp.51.1.21

Updated information and services can be found at:
<http://mp.bmj.com/content/51/1/21>

References

These include:

Article cited in:
<http://mp.bmj.com/content/51/1/21#related-urls>

Email alerting service

Receive free email alerts when new articles cite this article. Sign up in the box at the top right corner of the online article.

Notes

To request permissions go to:
<http://group.bmj.com/group/rights-licensing/permissions>

To order reprints go to:
<http://journals.bmj.com/cgi/reprintform>

To subscribe to BMJ go to:
<http://group.bmj.com/subscribe/>