

Short report

Monocyte chemotactic protein-1 in the inflammatory pseudotumour of the lung

E Pillozzi, A Stoppacciaro, E Rendina, L P Ruco

Abstract

Inflammatory pseudotumour of the lung is a lesion mainly composed of histiocytes. Histiocyte accumulation may arise from local proliferation of migratory cells, from cytokine induced recruitment of monocytes from the systemic circulation, or both. Cell proliferation was investigated with Ki-67 immunostaining and cytokine production with reverse transcriptase-polymerase chain reaction in two cases of inflammatory pseudotumour of the lung. It was found that the two lesions were composed mainly of non-proliferating (Ki-67 non-binding) macrophages that stained positive for CD68, CD14, CD4, and mannose receptor. Both cases contained mRNA transcripts for monocyte chemotactic protein-1 (MCP-1), a monocyte chemoattractant, and for interleukin 6 (IL-6), an inducer of plasma cell differentiation. One of the two cases also contained mRNA transcripts for IL-8, a neutrophil chemoattractant. These findings are consistent with the possibility that accumulation of non-proliferating histiocytes induced by MCP-1 is one of the pathogenic events occurring in inflammatory pseudotumour of the lung.

(*J Clin Pathol: Mol Pathol* 1998;51:50-52)

Keywords: inflammatory pseudotumour; chemokines; monocyte chemotactic protein-1; interleukin 8

Inflammatory pseudotumour of the lung is a poorly defined lesion of unknown cause composed of histiocytes, myofibroblasts, plasma cells, and lymphocytes.¹ On a quantitative basis, histiocytes are the main cellular component of most cases of inflammatory pseudotumour. Histiocyte accumulation may arise from local proliferation of migratory cells, from recruitment of monocytes from the systemic circulation, or both. Extravasation into tissues requires adhesion of circulating cells to activated endothelium,² and perivascular release of chemokines that are small inducible proteins characterised by the capacity specifically to attract leucocytes.^{3 4}

In two cases of inflammatory pseudotumour of the lung we investigated whether RNA transcripts for monocyte chemotactic protein-1 (MCP-1) and interleukin 8 (IL-8)—the most

representative members of α and β chemokines—were produced.

Materials and methods

PATIENTS

Patient 1 was an asymptomatic 35 year old woman who presented with a 3 cm lesion in the upper lobe of the left lung discovered incidentally during chest radiography. Computed tomography confirmed the presence of a well circumscribed, round, parahilar nodule. Fine needle aspiration and bronchial biopsy were inconclusive.

Patient 2 was an asymptomatic 64 year old man with a 4 cm lesion in the lower lobe of the right lung, discovered incidentally during chest radiography.

The two patients underwent surgical resection of their lesions. On gross examination, the lesions were nodular, well circumscribed, yellow-white, and measured 3 cm and 4.2 cm, respectively in diameter.

IMMUNOHISTOCHEMISTRY AND MOLECULAR BIOLOGY

Fresh fragments of the two nodules were snap frozen in liquid nitrogen and cryopreserved at -80°C until use. Immunohistochemical characterisation of the frozen sections was done using the avidin-biotin-peroxidase complex and monoclonal antibodies (Dako, Glostrup, Denmark) against CD68, CD4, CD14, vimentin, muscle specific actin, and desmin, as well as labelling with Ki-67. The PAM-1 monoclonal antibody, directed against the macrophage associated antigen mannose receptor, was kindly provided by Dr A Mantovani (Istituto M Negri, Milan, Italy). Other tissue fragments were fixed in 10% formalin and embedded in paraffin wax for conventional histology.

Total mRNA was isolated using the RNA fast isolation system (Molecular System, San Diego, California, USA) from frozen material. Ten micrograms of total RNA were used to synthesise single stranded cDNA. A reverse transcriptase (RT) reaction was done using 0.5 μg of random primers, 1 mM DTT, 0.5 mM dNTPs, 50 mM Tris HCl pH 8, 75 mM KCl, 3 mM MgCl, and 200 U of murine leukaemia virus reverse transcriptase (Gibco BRL, Maryland, USA). One tenth of the RT cDNA was added to 50 μl of solution

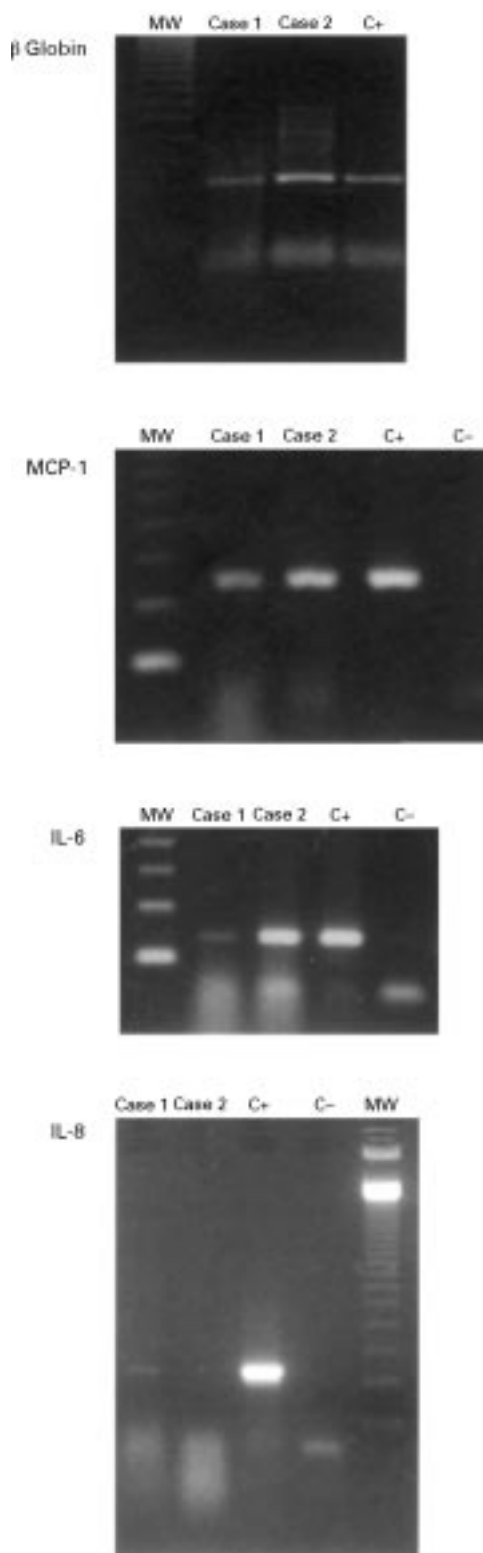
Dipartimento di
Medicina
Sperimentale e
Patologia, Policlinico
Umberto I, Università
"La Sapienza", Viale
Regina Elena 324,
00161 Roma, Italy
E Pillozzi
A Stoppacciaro
L P Ruco

Cattedra di Chirurgia
Toracica, Policlinico
Umberto I, Università
"La Sapienza"
E Rendina

Correspondence to:
Professor Ruco.
email: ruco@uniroma1.it

Accepted for publication
14 October 1997

Figure 1 RT-PCR amplification of β globin (256 base pairs), MCP-1 (354 base pairs), IL-6 (169 base pairs), and IL-8 (257 base pairs) mRNA in two cases of inflammatory pseudotumour of the lung, in normal lung (C-; negative control), and in endotoxin stimulated peripheral blood leucocytes (C+; positive control). MCP-1 and IL-6 were amplified in both cases of inflammatory pseudotumour. IL-8 was only detected in case 1. MW, molecular weight marker. Primers: β Globin 5'CAACTTCATCCACG TTCACG3'; 5'GAAGAGCCAAGG ACAGGTAC3'. IL-6, 5'GTGTGAAAGC AGCAAAGAG3'; 5'CTGGAGGTACTC TAGGTAT3'. MCP-1, 5'CTCAGCCA GATGCAATCAATGC3'; 5'CCTCAAGTCTTCG GACTTTGGG3'. IL-8, 5'TCTCAGCCCT CTTCAAAAACCTTCTC3'; 5'ATGACTTCCAAGC TGGCCGTGCT3'.



containing polymerase chain reaction (PCR) buffer (50 mM KCl, 1.5 mM MgCl₂, and 10 mM Tris HCl pH 8.3), 0.1 mM of each dNTP, 0.5 U of Taq polymerase (Perkin Elmer, Norwalk, Connecticut, USA), and 1 μ M of each primer (fig 1), and was amplified in a 9600 Perkin Elmer DNA thermal cycler. The PCR cycling parameters were: one cycle at 94°C for five minutes; 32 cycles at 94°C for 40 seconds, 54°C for one minute, and 72°C for

one minute; and one cycle at 72°C for five minutes.

Results

Histologically, patient 2 had a fibrous histiocytoma-type lesion, and patient 1 the plasma cell granuloma variant. Immunohistochemistry revealed that the majority of cells in both nodules were histiocytes and foamy macrophages, positive for the macrophage associated antigens CD68, CD14, CD4, and mannose receptor. Myofibroblasts were extremely rare as detected by immunostaining for muscle specific actin and desmin. An internal control for the two reactions was provided by vascular smooth muscle cells. Histiocyte proliferation was extremely low or absent as indicated by mitotic counts (0 in 10 high power fields in both cases) and by Ki-67 immunostaining. An internal control for the quality of the reactions was provided by some Ki-67 binding lymphocytes in the inflammatory infiltrates.

Presence of the chemokines MCP-1 and IL-8 was investigated in RNA extracts from the two lesions using RT-PCR. As shown in fig 1, RNA transcripts for MCP-1 were detected in both cases, whereas IL-8 was observed only in case 1. RNA extracted from a histologically normal lung was used as a negative control. RT-PCR for IL-6, already demonstrated in a pulmonary inflammatory pseudotumour⁵ was used as an additional control and was found positive in both cases.

Discussion

The heterogeneous histological manifestation of pulmonary inflammatory pseudotumour suggests strongly that it may encompass more than one entity. Pulmonary inflammatory pseudotumour is generally regarded as an inflammatory or reactive lesion rather than a neoplasm and 30% of patients have a history of pulmonary infection.⁶ However, a recent report describing clonal cytogenetic changes in a case of pulmonary inflammatory pseudotumour⁷ raised the possibility that some cases may represent benign or malignant neoplasms, perhaps deriving from pre-existing chronic inflammatory reactions.

The two inflammatory pseudotumours described in this study were composed mainly of histiocyte-like cells immunostained for monocyte macrophage antigens. Moreover, our findings suggest that histiocytic accumulation in the lesion was not sustained by proliferation of migratory cells, but was rather the result of local recruitment of circulating cells, perhaps favoured by the local production of MCP-1.

MCP-1 is produced by different cell types including macrophages, epithelial cells, fibroblasts, and endothelial cells, most of which are present in inflammatory pseudotumour lesions. MCP-1 binds to specific receptors on target cells and induces perivascular accumulation of monocytes and basophils. The presence of MCP-1 has been demonstrated in other pathological conditions of the lung such as granulomas, pleuritis, and idiopathic pulmonary fibrosis.⁸⁻¹⁰ These findings are consistent with the possibility that one of the pathogenic

events of inflammatory pseudotumour is a self maintaining reaction dependent on MCP-1 mediated recruitment of circulating monocytes.

MCP-1 is not the only molecule responsible for the inflammatory basis of inflammatory pseudotumour. In one of our two cases we detected RNA transcripts for IL-8, a chemokine that acts mainly on neutrophils, and in both cases we detected IL-6, a potent inducer of plasma cell differentiation. Thus, it seems reasonable to postulate that the inflammatory nature of inflammatory pseudotumour is determined by the action of various cytokines the secretion of which is activated by still unrecognised factors.

This work was supported by a grant from Associazione Italiana per la Ricerca sul Cancro.

- 1 Colby TV, Koss MN, Travis WD. Fibrous and fibrohistiocytic tumors and tumor-like conditions. In: Rosai J, Sobin LH, eds. *Tumors of the lower respiratory tract*. Third Series. Washington, DC: American Forces Institute of Pathology, 1995:327–52.
- 2 Gimbrone MA, Bevilacqua MP. Vascular endothelium. Functional modulation at the blood interface. In: Simionescu N, Simionescu M, eds. *Endothelial cell biology in health and disease*. New York: Plenum Press, 1988:255–74.
- 3 Baggolini M, Dewald B, Moser B. Interleukin-8 and related chemotactic cytokines CXC and CC chemokines. *Adv Immunol* 1994;55:97–179.
- 4 Furie MB, Randolph GJ. Chemokines and tissue injury. *Am J Pathol* 1995;146:1287–301.
- 5 Röhrlich P, Peuchmaur M, De Napoli Ciocci S, et al. Interleukin-6 and interleukin-1b in a pediatric plasma cell granuloma of the lung. *Am J Surg Pathol* 1995;19:590–5.
- 6 Matsubara O, Tan Liu NS, Kennedy RM, et al. Inflammatory pseudotumors of the lung: progression from organizing pneumonia to fibrous histiocytoma or to plasma cell granuloma in 32 cases. *Hum Pathol* 1988;19:807–14.
- 7 Snyder CS, Dell'Aquila M, Haghghi P, et al. Clonal changes in inflammatory pseudotumor of the lung. *Cancer* 1995;76:1545–9.
- 8 Flory CM, Jones ML, Warren JS. Pulmonary granuloma formation in the rat is partially dependent on monocyte chemoattractant protein-1. *Lab Invest* 1993;69:396–404.
- 9 Antony VB, Godbey SW, Kunkel SL, et al. Recruitment of inflammatory cells to pleural space. Chemotactic cytokines and monocyte chemoattractant peptide-1 in human pleural fluids. *J Immunol* 1993;151:7216–23.
- 10 Iyonaga K, Takeia M, Saita N, et al. Monocyte chemoattractant protein-1 in idiopathic pulmonary fibrosis and other interstitial lung diseases. *Hum Pathol* 1994;25:455–63.



Monocyte chemotactic protein-1 in the inflammatory pseudotumour of the lung.

E Pillozzi, A Stoppacciaro, E Rendina, et al.

Mol Path 1998 51: 50-52
doi: 10.1136/mp.51.1.50

Updated information and services can be found at:
<http://mp.bmj.com/content/51/1/50>

Email alerting service

These include:

Receive free email alerts when new articles cite this article. Sign up in the box at the top right corner of the online article.

Notes

To request permissions go to:
<http://group.bmj.com/group/rights-licensing/permissions>

To order reprints go to:
<http://journals.bmj.com/cgi/reprintform>

To subscribe to BMJ go to:
<http://group.bmj.com/subscribe/>