

Short report

Identification of a novel PTEN mutation (L139X) in a patient with Cowden disease and Sjögren's syndrome

A M Raizis, M M Ferguson, B A Robinson, C H Atkinson, P M George

Abstract

Cowden disease is an autosomal dominant disorder associated with an increased risk of breast, thyroid, and skin cancer in which germline mutations in a candidate tumour suppressor gene (PTEN) have been identified previously. Sjögren's syndrome is a chronic inflammatory and autoimmune disorder of exocrine glands for which the genetic basis is unknown. This report describes a novel PTEN mutation (L139X) in a patient with Cowden disease and Sjögren's syndrome. This observation raises the possibility of a link between mutations in the PTEN gene and Sjögren's syndrome.

(*J Clin Pathol: Mol Pathol* 1998;51:339–341)

Keywords: Cowden disease; Sjögren's syndrome; PTEN gene; mutation

Cowden disease (OMIM 158350), also known as multiple hamartoma syndrome, involves a single locus on chromosome 10q23¹ at which PTEN (Genbank AF000734), a candidate tumour suppressor gene, has been identified.^{2 3} PTEN has a putative protein tyrosine phosphatase domain as well as tensin homology and is mutated in patients with Cowden disease.^{1 4 5}

In Sjögren's syndrome (OMIM 270150), exocrine glands undergo progressive destruction by lymphocytes and plasma cells, resulting in decreased production of secretions. The salivary and lacrimal glands are involved most frequently. In some cases, Sjögren's syndrome segregates in a Mendelian dominant manner and is thought to be the result of an interaction between several human leucocyte antigen (HLA) linked and non-HLA linked genes.⁶ However, the genes that might predispose to Sjögren's syndrome have yet to be characterised. Interestingly, Sjögren's syndrome is associated with a benign infiltrative lymphoproliferation and increased lymphoma risk.

Here, we report a patient with a novel PTEN mutation (L139X) and the clinical features of both Cowden disease and Sjögren's syndrome.

Materials and methods

PATIENTS

A 41 year old woman presented with "warts" in and around her mouth. These had first appeared at the age of 24 years. Examination revealed multiple polyps on the commissures, labial and buccal mucosae, dorsum of the tongue, and the soft palate. These had been present for at least 12 years. Histology of the oral lesions was consistent with condylomata, but typing for human papilloma virus (HPV) 6/11, 31/33, 16, and 18 was negative. Plain warts were also noted on her hands, with histology being reported as a verruca. There were no other skin lesions, facial papules, or trichilemmomas. Initial treatment was with interferon 2 α but this was stopped after the diagnosis was revised to Cowden disease.⁷ Perusal of family photographs indicated that by the age of 5 years the cranium appeared slightly larger than normal, with bossing of the forehead. Cranial circumference as an adult is 59 cm. An ultrasound scan of her thyroid showed a multinodular goitre; thyroid function tests were normal and thyroid autoantibodies were not detected. However, mammography and ultrasound revealed a 2 cm infiltrating breast carcinoma, which was treated by mastectomy followed by chemotherapy. Colonoscopy did not demonstrate any polyps. The patient has four children, of which three showed cranial circumferences greater than normal. Two of these three children had changes in their oral mucosa that are consistent with Cowden disease.⁷

During the course of these investigations the patient developed acute swelling of the left parotid gland. No saliva could be expressed from the duct orifice and the situation resolved spontaneously after two weeks. Six similar episodes had occurred in the previous five years. In addition to this, the patient complained of a persistent dry mouth. This problem has continued, requiring the use of pilocarpine systemically as sialagogue. Serology showed positive antinuclear antibodies, rheumatoid factor anti-SS-A (Ro) and anti-SS-B (La) as well as hypergammaglobulinaemia. A plain radiograph revealed numerous, small calcified areas, and histology of the parotid gland showed a chronic

Department of Clinical Biochemistry, Christchurch Hospital, Christchurch 8001, New Zealand

A M Raizis
P M George

Department of Oncology, Christchurch Hospital
B A Robinson
C H Atkinson

Department of Stomatology, University of Otago, Dunedin 9001, New Zealand
M M Ferguson

Correspondence to:
Dr George.
email:
pgeorge@chmeds.ac.nz

Accepted for publication
7 July 1998

inflammatory infiltrate with areas of calcification. A diagnosis of Sjögren's syndrome was made based on the xerostomia, serology, and histology. Although the calcified areas were considered unusual, this appearance has been associated with a chronic inflammatory process.

PCR ANALYSIS OF THE PTEN GENE

To detect the PTEN mutation, genomic DNA was extracted from the patient's blood. Exon 5 was amplified by the polymerase chain reaction (PCR) using intronic primers⁵ and a 402 bp product was obtained using a 5' forward primer (5'-ACCTGTAAAGTTTGTATGCAA-3') and a 3' reverse primer (5'-TCCAGGAAGAGGAAAGGAAA-3'). The 3' reverse primer was also used for DNA sequencing. The amplification conditions were 94°C for five minutes followed by 30 cycles of 94°C for one minute, 53°C for one minute, and 72°C for one minute, with a final extension time of seven minutes at 72°C. DNA sequencing was performed directly on the PCR product by the thermocycling technique using Amersham thermosequase (Amersham Life Sciences, Amersham, Buckinghamshire, UK) and ³²P labelled dideoxy nucleotide triphosphate chain terminators, according to manufacturers instructions.

RESTRICTION ANALYSIS

To confirm the base substitution, a restriction enzyme assay was designed using the above 5' forward primer and a mutagenic 3' reverse primer (5'-AAAAATTTGCCCGATGTGAT-3') corresponding to nucleotides 214–235 of exon 5 (GenBank AF000730). To generate a MboI restriction cutting site specific for the mutation, a "G" was positioned at nucleotide 216 (normally "A"), such that MboI cleaved the mutant (L139X) allele but not the wild-type allele. Using these primers, the genomic DNA was amplified by PCR with the same conditions as above except that the annealing temperature was lowered to 47°C. The PCR product was analysed by polyacrylamide gel electrophoresis after incubation with 5 U of MboI.

Results

Direct DNA sequence analysis of exons 3, 4, 5, and 7 revealed that the patient was heterozygous for a base substitution in exon 5 of the PTEN gene (fig 1A). This exon encodes 79 amino acids (86–164) and, in the patient, codon 139 is mutated (TTA to TGA), resulting in a premature stop codon and truncation of the PTEN molecule. The mutation was confirmed by MboI restriction enzyme analysis and was also detected in three of the patient's four children (fig 1B). Because the three heterozygous children (aged 10–14 years) already have macrocephaly and two of them have oral mucosal changes, the data are consistent with the PTEN mutation segregating with affected individuals. The patient's mother did not have the L139X mutation, but we were unable to test her father, who was dead. Photographs of this man do not show frontal bossing and his mouth was reportedly normal in the notes of two hospital admissions.

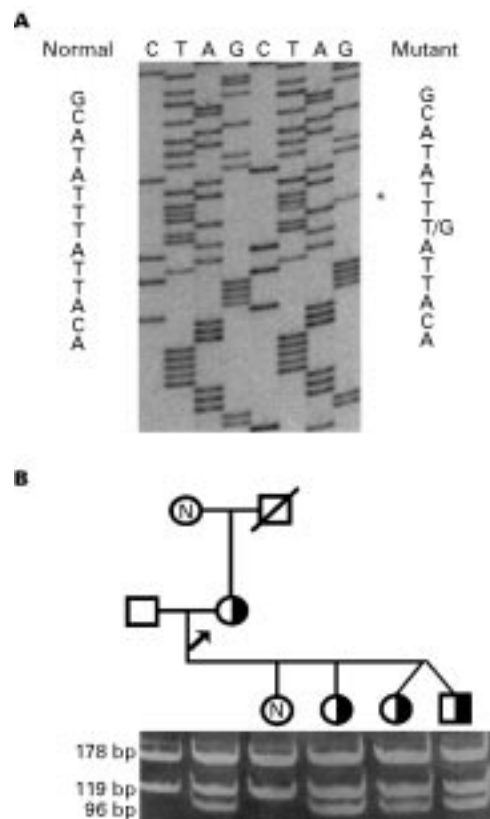


Figure 1 Genetic analysis of a family with Cowden disease. (A) sequence analysis of the PTEN gene from a normal control (left) and the proband (right). Exon 5 was amplified by PCR and the product was purified and sequenced using the reverse primer. The proband is heterozygous for a T to G mutation (asterisk) encoding L139X. (B) Restriction analysis of PTEN mutation L139X in the proband's family. Circles, females; squares, males; clear symbols, not tested; N, normal; hatched symbols, heterozygotes; the arrow indicates the proband. A 297 bp PCR product was generated with the 5' forward primer and a mutagenic primer that introduces a MboI site in the mutant allele. Digests were separated on a 12% native polyacrylamide gel and stained with ethidium bromide.

We have screened over 50 other members of this kindred, of which none shows the L139X mutation (not shown), thus suggesting that the mutation occurred de novo.

Discussion

We have identified a novel PTEN (L139X) mutation in a patient with Cowden disease and Sjögren's syndrome. This mutation results in truncation of the PTEN molecule and most likely leads to its inactivation. However, it is not clear whether specific PTEN mutations are responsible for a particular phenotype. For example, this patient has many features consistent with Cowden disease but has no bowel lesions. In contrast, it has been shown recently that some PTEN mutations give rise to juvenile polyposis coli with little or no features of Cowden disease.⁸ These observations suggest either that different mutations have varying phenotypic effects or that other gene loci are involved.

Although Sjögren's syndrome and Cowden disease are not usually associated, mutations in the PTEN gene might predispose to Sjögren's syndrome. Both Cowden disease and Sjögren's syndrome are characterised by benign proliferations, that is, multiple hamartomas in

Cowden disease and lymphoproliferation in Sjögren's syndrome. Furthermore, both tumorigenesis and Sjögren's syndrome are thought to involve the impairment of apoptosis.^{9 10}

It is interesting that non-Hodgkins lymphoma has been associated with Cowden disease¹¹ and is often seen in patients with Sjögren's syndrome. Cytogenetic abnormalities occur frequently at chromosome 10q23–25 in non-Hodgkins lymphoma, suggesting that a tumour suppressor gene occurs at this chromosomal location.¹² PTEN is a tumour suppressor gene that maps to 10q23.3,³ and it may have a role in non-Hodgkins lymphoma. Currently, we and others are testing this possibility by screening sporadic lymphoma samples for PTEN mutations (C. Eng, pers. commun., 1998).

There are several other interesting clinical features in this patient. The occurrence of atypical calcified areas within the inflammatory infiltrate of the parotid gland suggests a complication that may reflect the association with Cowden disease. Although calcification of lipomas occurs in Cowden disease, the cause of calcification remains unknown. We also noted that, despite careful clinical evaluation, this patient does not have facial papules or trichilemmomas, a hallmark of Cowden disease.¹ As with other disorders, the availability of direct gene analysis might allow the recognised clinical spectrum within Cowden disease to be broadened.

This work was supported by the McClelland and Oncology Trust funds, Christchurch, and Dr I Smith (Research and International Bridging Grant) Otago, New Zealand. We would like to acknowledge the role of Drs R Robertson, L Snape, and D Goodisson in the clinical care of this patient and the collection of blood samples. We would also like to thank Drs I Al-Hashimi, N Rhodus, and J O'Donnell for their assistance in the diagnosis of Sjögren's syndrome.

- 1 Nelen MR, Padberg GW, Peeters, EA, *et al.* Localization of the gene for Cowden disease to chromosome 10q22–23. *Nat Genet* 1996;**13**:114–16.
- 2 Li J, Yen C, Liaw D, *et al.* PTEN, a putative protein tyrosine phosphatase gene mutated in human brain, breast, and prostate cancer. *Science* 1997;**275**:1943–7.
- 3 Steck PA, Pershouse MA, Jasser SA, *et al.* Identification of a candidate tumour suppressor gene, MMAC1, at chromosome 10q23.3 that is mutated in multiple advanced cancers. *Nat Genet* 1997;**15**:356–62.
- 4 Marsh DJ, Zheng Z, Zedenius J, *et al.* Differential loss of heterozygosity in the region of the Cowden locus within 10q22–23 in follicular thyroid adenomas and carcinomas. *Cancer Res* 1997;**57**:500–3.
- 5 Liaw D, Marsh DJ, Li J, *et al.* Germline mutations of the PTEN gene in Cowden disease, an inherited breast and thyroid cancer syndrome. *Nat Genet* 1997;**16**:64–7.
- 6 Reveille JD, Wilson RW, Provost TT, *et al.* Primary Sjögren's syndrome and other autoimmune diseases in families. Prevalence and immunogenetic studies in six kindreds. *Ann Intern Med* 1984;**101**:748–56.
- 7 Hanssen AMN, Fryns JP. Cowden syndrome. *J Med Genet* 1995;**32**:117–19.
- 8 Olschwang S, Serova-Sinilnikova OM, Lenoir G, *et al.* PTEN germ-line mutations in juvenile polyposis coli. *Nat Genet* 1998;**18**:12–14.
- 9 Manganelli P, Quaini F, Andreoli AM, *et al.* Quantitative analysis of apoptosis and bcl-2 in Sjögren's syndrome. *J Rheumatol* 1997;**24**:1552–7.
- 10 Rowan S, Fisher DE. Mechanisms of apoptotic cell death. *Leukemia* 1997;**11**:457–65.
- 11 Elston DM, James WD, Rodman OG, *et al.* Multiple hamartoma syndrome (Cowden's disease) associated with non-Hodgkin's lymphoma. *Arch Dermatol* 1986;**122**:572–5.
- 12 Speaks SL, Sanger WG, Masih AS, *et al.* Recurrent abnormalities of chromosome bands 10q23–25 in non-Hodgkin's lymphoma. *Genes Chromosomes Cancer* 1992;**5**:239–43.



Identification of a novel PTEN mutation (L139X) in a patient with Cowden disease and Sjögren's syndrome.

A M Raizis, M M Ferguson, B A Robinson, et al.

Mol Path 1998 51: 339-341
doi: 10.1136/mp.51.6.339

Updated information and services can be found at:
<http://mp.bmj.com/content/51/6/339>

	<i>These include:</i>
References	Article cited in: http://mp.bmj.com/content/51/6/339#related-urls
Email alerting service	Receive free email alerts when new articles cite this article. Sign up in the box at the top right corner of the online article.

Notes

To request permissions go to:
<http://group.bmj.com/group/rights-licensing/permissions>

To order reprints go to:
<http://journals.bmj.com/cgi/reprintform>

To subscribe to BMJ go to:
<http://group.bmj.com/subscribe/>