

HHV-8 (KSHV) is not associated with bacillary angiomatosis

S J Nayler, U Allard, L Taylor, K Cooper

Abstract

Aims—Bacillary angiomatosis is a rare pseudoneoplastic angioproliferative lesion occurring in patients with AIDS. This condition has been associated with *Bartonella henselae* and *Bartonella quintana* infections. Human herpesvirus 8 (HHV-8) is thought to be the causative agent of Kaposi's sarcoma, a vasoproliferative neoplasm, also commonly found in patients with AIDS. The presence of HHV-8 in a cohort of patients with bacillary angiomatosis was investigated.

Methods—Eight cutaneous cases of biopsy confirmed bacillary angiomatosis were assessed for HHV-8 using standard solution phase polymerase chain reaction (PCR).

Results—No case of bacillary angiomatosis harboured HHV-8 DNA.

Conclusions—HHV-8 was not demonstrated in the lesions of bacillary angiomatosis and therefore does not appear to play a role in the pathogenesis of this pseudoneoplastic angioproliferative disorder. This finding might be useful in the distinction of bacillary angiomatosis from Kaposi's sarcoma, because lesions from patients with Kaposi's sarcoma almost always contains HHV-8 DNA.

(J Clin Pathol: Mol Pathol 1999;52:345-348)

Keywords: bacillary angiomatosis; human herpesvirus 8; Kaposi's sarcoma; polymerase chain reaction

Bacillary angiomatosis is a pseudoneoplastic disease characterised by angioproliferative lesions involving skin and deep viscera.¹ Virtually all cases have occurred in the setting of advanced AIDS.² This condition was first described in the USA in 1983³ and in South Africa in 1993.⁴ The causative organisms implicated are *Bartonella henselae* and *Bartonella quintana*⁵ (formerly *Rochalimea henselae* and *Rochalimea quintana*, respectively⁶).

The newly described human herpesvirus 8 (HHV-8),³ also known as Kaposi's sarcoma associated herpes virus (KSHV), has been shown to be associated with all forms of Kaposi's sarcoma,^{7,8} including AIDS associated Kaposi's sarcoma, classic, African endemic, and the transplant associated forms.⁹⁻¹² HHV-8 has also been implicated in the pathogenesis of a wide number of human neoplasms.¹³⁻¹⁵

Bacillary angiomatosis can be clinically mistaken for Kaposi's sarcoma and although most cases demonstrate characteristic histological features (fig 1A-C), with lobular proliferations of capillaries, lined by plump endothelial cells associated with aggregates of neutrophils scat-

tered throughout the lesion, occasional cases have in our experience shown areas resembling Kaposi's sarcoma (fig 1D).

Because both conditions are vasoformative lesions associated with infective organisms, we undertook this study to establish whether there is an association between human herpesvirus 8 and bacillary angiomatosis.

Methods

Eight cases of previously diagnosed bacillary angiomatosis, from seven patients (two separate sites from one patient), were retrieved from the archives of the department of anatomical pathology, South African Institute for Medical Research and University of the Witwatersrand. Two cases had been described previously.^{4,16} Two of the patients were white homosexual men, the remaining five patients were heterosexual black Africans, who had acquired the human immunodeficiency virus sexually. No patient had biopsy confirmed Kaposi's sarcoma concurrently. Table 1 summarises the clinical details.

Sections (2-4 µm thick) were cut from paraffin wax embedded tissue, floated out, and picked up on to glass slides. These were then air dried, dewaxed, and hydrated through sequential baths of xylene and alcohol, respectively, before a final rinse in distilled water. The sections were then allowed to dry. Strict anticontamination procedures were followed.

DNA was extracted from the tissue using the QIAmp kit (Qiagen, Dorking, Surrey, UK). The tissue was digested overnight in proteinase K at 55°C, precipitated with ethanol, and bound in a spin column, before final elution in water.

Two rounds of nested polymerase chain reaction (PCR) were performed on a Perkin Elmer Geneamp PCR system (Perkin Elmer, Norwalk, Connecticut, USA). Initially, 2 µl of DNA were added to a reaction mixture containing 0.2 µM of each of the primers KS4 (5'-AGCACTCGCAGGGCAG TACG-3') and KS5 (5'-GACTCTTCGCTG ATGAACTGG-3'). Each 50 µl contained 10 mM of Tris/HCl, 50 mM of KCl, 2 mM of MgCl₂, 1.5 U of Taq polymerase, and 0.1 mM dNTP (Boehringer Mannheim, Randburg, South Africa). A second reaction using internal primers KS1 (5'-AGCCGAAAGGATTCCA CCAT-3') and KS2 (5'-TCCGTGTT GTCTACGTCCAG-3') was performed on 4 µl of the amplicon obtained from the first reaction. The reaction mixture was identical to that used above.

Thermocycling conditions were as follows: first round: 30 cycles of 45 seconds at 94°C, 30 seconds at 60°C, and 45 seconds at 72°C. The

Department of Anatomical Pathology, School of Pathology, South African Institute for Medical Research, and University of the Witwatersrand, PO Box 1038, Johannesburg 2000, South Africa
S J Nayler
U Allard
L Taylor
K Cooper

Correspondence to:
Dr Nayler
email:
simonn@mail.saimr.wits.ac.za

Accepted for publication
15 July 1999

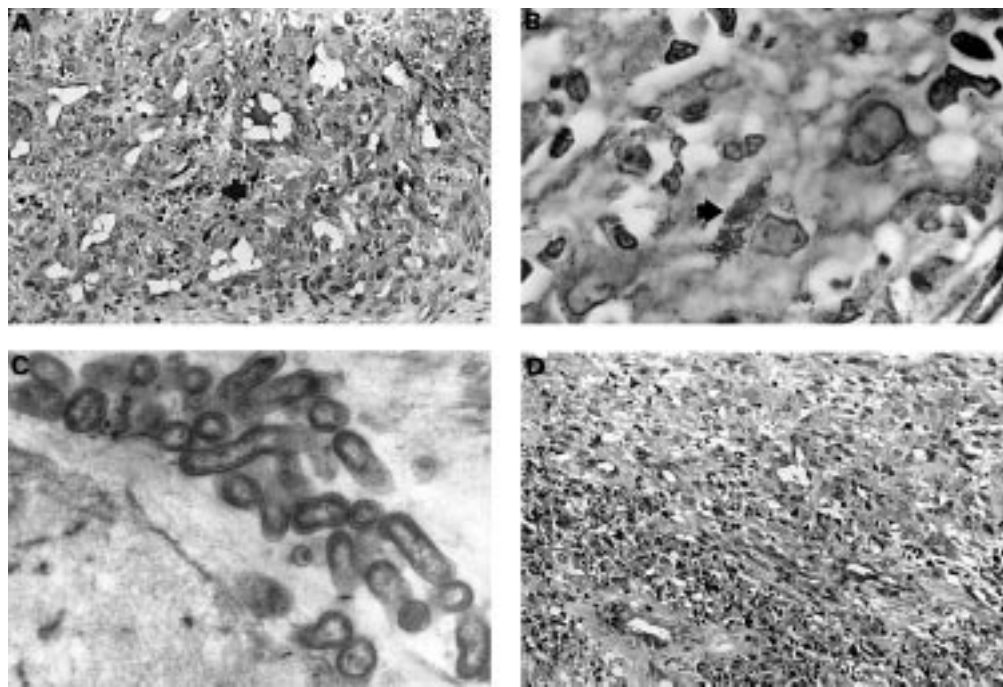


Figure 1 (A) Haematoxylin and eosin stain of characteristic lesion in bacillary angiomatosis, showing collections of neutrophils and leucocytoclastic debris (arrow), with prominent blood vessels lined by plump, epithelioid endothelial cells (magnification, $\times 200$). (B) Clusters of argyrophilic bacteria (arrow) are identified in the interstitium of this lesion (Warthin-Starry stain; magnification, $\times 1000$). (C) Electron micrograph showing bacilli with trilaminar cell walls (magnification, $\times 21\,960$). (D) Photomicrograph of kaposiform areas, seen at the periphery of the typical lesion of bacillary angiomatosis shown in (A).

second round was similar, but with an annealing temperature of 55°C .

Positive controls were performed, using DNA extracted from a Kaposi's sarcoma lesion, and appropriate negative controls comprised tissue not containing HHV-8 from immunocompetent patients, and a blank control with water substituted for the DNA. The DNA was electrophoresed on a 3% agarose gel and visualised with ethidium bromide. The size of the DNA fragment (233 bp) was established by comparison with a standard molecular weight marker (Marker V; Boehringer Mannheim). The sensitivity of this method has been shown to be one HHV-8 copy/10 000 uninfected cells.¹⁷

Amplification of the β -globin gene, under the same conditions described above, was performed to establish the integrity of the DNA preparations, as described previously.¹⁸ A 10 μl aliquot of extracted DNA was amplified with primers PCO4 (5'-CAACTTCATCCACGTTCACC-3') and GH20 (5'-GAAGAGCCAAGGACAGGTAC-3'). Each

reaction contained 10 mM Tris/HCl, 50 mM KCl, 4 mM MgCl_2 , 200 μM each dNTP, 2.5 U Taq polymerase, and 0.5 μM of each β -globin primer.

Amplification conditions were as follows: "hot start" of 94°C for four minutes, followed by 40 cycles of 95°C for one minute, 55°C for one minute, then 72°C for one minute. The final extension was for five minutes at 72°C . The amplicons were visualised on a 3% agarose gel stained with ethidium bromide. The anticipated size of the DNA fragment was 268 bp.

Three replicate assays were performed for each sample.

Results

HHV-8 DNA sequences were not detected in the eight cases of bacillary angiomatosis. The Kaposi's sarcoma control contained HHV-8, whereas the negative controls were devoid of these DNA sequences. Figure 2 shows these results. Each of the specimens successfully amplified DNA sequences for the β -globin

Table 1 Clinical data of seven HIV positive patients with bacillary angiomatosis

Sample	Sex	Age	Site	Presentation
1	F	36	Skin	Angiomatous papules face, trunk, and palate
2	M	45	Skin	Angiomatous nodules on thigh and penis: clinically Kaposi's sarcoma
3	F	42	Skin (thigh)	Ulcerating nodular lesion: ?Kaposi's sarcoma
4*	M	28	Skin (thigh)	Pustular, angiomatous lesions on face, trunk, and legs
5*	M	28	Skin (abdomen)	Pustular, angiomatous lesions on face, trunk, and leg
6	M	40	Skin	Clinically Kaposi's sarcoma
7	M	28	Skin (thigh)	Tender, ulcerated nodule on thigh, possible Kaposi's sarcoma or carbuncle
8	M	27	Skin (left submandibular area)	Angiomatous lesion, possible Kaposi's sarcoma

*Same patient.
F, female; M, male.

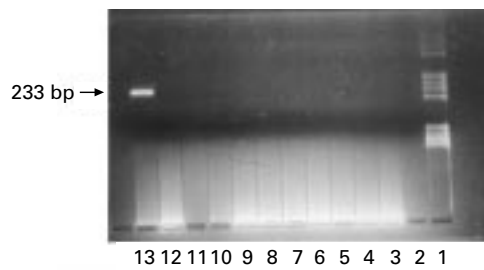


Figure 2 Gel electrophoresis of PCR amplified products corresponding to human herpesvirus 8 DNA sequences (233 bp). Lane 1, molecular weight marker; lane 2, blank; lane 3, blank; lane 4, negative control; lane 5, patient 1; lane 6, patient 2; lane 7, patient 3; lane 8, patient 4; lane 9, patient 5; lane 10, patient 6; lane 11, patient 7; lane 12, patient 8; lane 13, positive control (Kaposi's sarcoma).

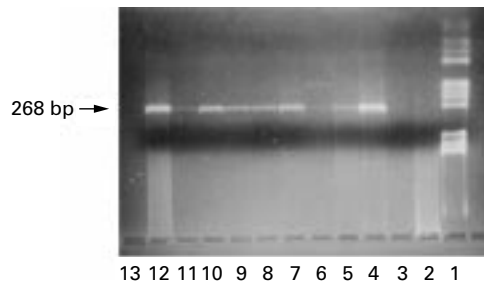


Figure 3 Gel electrophoresis of PCR amplified products corresponding to β -globin gene (268 bp). Lane 1, molecular weight marker; lane 2, negative control; lane 3, blank; lane 4, patient 1; lane 5, patient 2; lane 6, patient 3; lane 7, patient 4; lane 8, patient 5; lane 9, patient 6; lane 10, patient 7; lane 11, patient 8; lane 12, positive control; lane 13, blank.

chain, indicating that the extracted DNA was adequately preserved (fig 3).

Discussion

Bacillary angiomatosis is a rare pseudoneoplastic vascular proliferation, occurring almost exclusively in the setting of the severe immunosuppression seen with AIDS. The role of *B henselae* and *B quintana* as the causative agents of this potentially life threatening but treatable disease is well established.^{5 6}

Since the discovery of HHV-8 and the elucidation of its role in the pathogenesis of Kaposi's sarcoma, to our knowledge, there have been no studies investigating whether or not HHV-8 plays a role in the pathogenesis of bacillary angiomatosis.

Because bacillary angiomatosis and Kaposi's sarcoma are both vasoproliferative lesions, occurring in immunosuppressed individuals, it seemed logical to hypothesise that HHV-8 might play a role in the pathogenesis of bacillary angiomatosis. Indeed, controversy exists as to whether Kaposi's sarcoma is a true neoplasm or merely a reactive process induced by HHV-8.¹⁹

In our hands, HHV-8 DNA sequences can be demonstrated in all cases of Kaposi's sarcoma (in both HIV positive and negative patients).²⁰ The demonstration of HHV-8 is also an extremely useful diagnostic adjunct in equivocal cases of the early patch stage of Kaposi's sarcoma.²¹ In this regard, it has been suggested that the presence of HHV-8 might be a reliable marker for the diagnosis of Kaposi's sarcoma.^{22 23} However, the specificity might be

lower than thought initially, because of the demonstration of HHV-8 in histologically unaffected tissues in patients with Kaposi's sarcoma.²³ Furthermore, a study has also demonstrated the presence of HHV-8 in prostatic tissues of non-immunosuppressed patients.²⁴ However, this has not been confirmed in other studies.^{25 26}

Other vascular tumours can mimic Kaposi's sarcoma histologically, particularly angiosarcomas, spindle cell haemangioma, and kaposiform haemangioma. The absence of HHV-8 DNA sequences in these lesions, as well as their absence in a range of other vascular neoplasms, has also been demonstrated.²⁷ Thus, the demonstration of HHV-8 in a vascular lesion with the histomorphology of Kaposi's sarcoma should be regarded as being specific for Kaposi's sarcoma.

Our data indicate that HHV-8 is not associated with bacillary angiomatosis. For practical purposes this might have useful implications for histopathologists, in distinguishing between these two entities. Bacillary angiomatosis, in most instances, has characteristic histopathological features, which allow it to be distinguished from Kaposi's sarcoma. In our experience, occasional cases of bacillary angiomatosis can show areas within the lesion that are virtually indistinguishable from Kaposi's sarcoma.

In cases in which histological differentiation between these two vasoproliferative lesions is not clear, the demonstration of HHV-8 could definitively establish the diagnosis of Kaposi's sarcoma. In contradistinction, the demonstration of HHV-8 would be against a diagnosis of bacillary angiomatosis. This distinction has important clinical implications, because bacillary angiomatosis responds well to appropriate antibiotic treatment, the institution of which may be lifesaving.

In summary, we have shown that bacillary angiomatosis is not associated with HHV-8. This finding supports the growing body of evidence that HHV-8 is a specific marker for Kaposi's sarcoma, and is not found in other vasoproliferative lesions and tumours.

- Cockrell CJ, Webster GF, Whitlow MA, *et al*. Epithelioid angiomatosis: a distinct vascular disorder in patients with the acquired immunodeficiency syndrome or AIDS related complex. *Lancet* 1987;2:654-6.
- Adal KA, Cockrell CJ, Petri WA. Current concepts: cat scratch disease, bacillary angiomatosis, and other infections due to rochalimaea. *N Engl J Med* 1994;330:1509-15.
- Stoler MH, Bonfiglio TA, Steigbigel RT, *et al*. An atypical subcutaneous infection associated with acquired immune deficiency syndrome. *Am J Clin Pathol* 1983;80:714-18.
- Levy GR, Naylor SJ. Bacillary angiomatosis: the first case reported in South Africa. *S Afr Med J* 1993;83:855-6.
- Cockrell CJ. Bacillary angiomatosis and related disease caused by rochalimaea. *J Am Acad Dermatol* 1995;32:783-90.
- Brenner DJ, O'Connor SP, Wrinkler HH, *et al*. Proposals to unify the genera bartonella and rochalimaea, with descriptions of *Bartonella quintana* comb. nov., *Bartonella vinsonii* comb. nov., *Bartonella henselae* comb. nov., and *Bartonella elizabethae* comb. nov., and to remove the family bartonellaceae from the order rickettsiales. *Int J Syst Bacteriol* 1993;43:777-86.
- Chang Y, Cesarman E, Pessin MS, *et al*. Identification of herpesvirus-like DNA sequences in AIDS-associated Kaposi's sarcoma. *Science* 1994;266:1865-9.
- Kennedy MM, Cooper K, Howells DD, *et al*. Identification of HHV8 in early Kaposi's sarcoma: implications for Kaposi's sarcoma pathogenesis. *J Clin Pathol: Mol Pathol* 1998;51:14-20.

- 9 Ambroziak JA, Blackburn DJ, Herndier BG, et al. Herpes-like sequences in HIV-infected and uninfected Kaposi's sarcoma patients. *Science* 1995;268:582-3.
- 10 Huang YQ, Li JJ, Kaplan MH, et al. Human herpesvirus-like nucleic acid in various forms of Kaposi's sarcoma. *Lancet* 1995;345:759-61.
- 11 Boshoff C, Whitby D, Hatzioannou T, et al. Kaposi's sarcoma-associated herpesvirus in HIV-negative Kaposi's sarcoma. *Lancet* 1995;345:1043-4.
- 12 Chang Y, Ziegler J, Wabinga H, et al. Kaposi's sarcoma-associated herpesvirus and Kaposi's sarcoma in Africa. *Arch Intern Med* 1996;156:202-4.
- 13 Cesarman E, Chang Y, Moore PS, et al. Kaposi's sarcoma-associated herpesvirus-like DNA in AIDS-related body-cavity-based lymphomas. *N Engl J Med* 1995;332:1186-91.
- 14 McDonagh DP, Liu J, Gaay MJ, et al. Detection of Kaposi's sarcoma-associated herpesvirus-like DNA sequences in angiosarcoma. *Am J Pathol* 1996;149:1363-8.
- 15 Cesarman E, Knowles D. Kaposi's sarcoma-associated herpesvirus: a lymphotropic human herpesvirus associated with Kaposi's sarcoma, primary effusion lymphoma, and multicentric Castlemans disease. *Semin Diagn Pathol* 1997;14:54-66.
- 16 Burgin S, Spencer DC. Bacillary angiomatosis—another South African case [letter]. *S Afr Med J* 1996;86:95-6.
- 17 Boshoff C, Talbot S, Kennedy M, et al. HHV8 and skin cancers in immunosuppressed patients. *Lancet* 1996;347:338-9.
- 18 Bauer HM, Greer CE, Manos MM. Determination of the genital HPV infection by consensus polymerase chain reaction amplification. In: Herrington CS, McGee JO'D, eds. *Diagnostic molecular pathology: a practical approach*. Vol. 2. Oxford: Oxford University Press, 1992:131-51.
- 19 Fletcher CDM. Soft tissue tumours: an update. In: Anthony PP, MacSween RNM, eds. *Recent advances in histopathology*. Vol. 15. Edinburgh, UK: Churchill Livingstone, 1992:113-39.
- 20 Sitas F, Taylor L, Madhoo J, et al. Occurrence of human herpes virus 8 in Kaposi's sarcoma and other tumours in South Africa [letter]. *S Afr Med J* 1997;87:1020-1.
- 21 Maoirana A, Luppi M, Barozzi P, et al. Detection of human herpesvirus type 8 DNA sequences as a valuable aid in the differential diagnosis of Kaposi's sarcoma. *Mod Pathol* 1997;10:182-7.
- 22 O'Leary JJ, Kennedy MM, McGee JOD. Kaposi's sarcoma-associated herpesvirus (KSHV/HHV-8): epidemiology, molecular biology, and tissue distribution. *J Clin Pathol: Mol Pathol* 1997;10:182-7.
- 23 Cathomas G, Stalder A, McGandy CE, et al. Distribution of human herpesvirus 8 DNA in tumorous and nontumorous tissue of patients with acquired immunodeficiency syndrome with and without Kaposi's sarcoma. *Mod Pathol* 1998;11:415-20.
- 24 Monini P, DeLellis L, Fabris D, et al. Kaposi's sarcoma-associated herpesvirus DNA sequences in prostatic tissue and human semen. *N Engl J Med* 1996;334:1168-72.
- 25 Hubbard R, Lewontin RC. Absence of HHV-8 in prostate and semen [letter]. *N Engl J Med* 1996;335:1119.
- 26 Tasaki T, Said JW, Morosetti R, et al. Is Kaposi's sarcoma-associated herpesvirus ubiquitous in urogenital and prostatic tissues? *Blood* 1997;89:1686-9.
- 27 Hisaoka M, Hashimoto H, Iwamasa T. Diagnostic implications of Kaposi's sarcoma-associated herpesvirus with special reference to the distinction between spindle cell haemangioma and Kaposi's sarcoma. *Arch Pathol Lab Med* 1998;122:72-6.



HHV-8 (KSHV) is not associated with bacillary angiomatosis.

S J Nayler, U Allard, L Taylor, et al.

Mol Path 1999 52: 345-348

doi: 10.1136/mp.52.6.345

Updated information and services can be found at:

<http://mp.bmj.com/content/52/6/345>

Email alerting service

These include:

Receive free email alerts when new articles cite this article. Sign up in the box at the top right corner of the online article.

Notes

To request permissions go to:

<http://group.bmj.com/group/rights-licensing/permissions>

To order reprints go to:

<http://journals.bmj.com/cgi/reprintform>

To subscribe to BMJ go to:

<http://group.bmj.com/subscribe/>