

Acute lymphoblastic leukaemia: correlation between morphological/immunohistochemical and molecular biological findings in bone marrow biopsy specimens

S M Kröber, A Greschniok, E Kaiserling, H-P Horny

Abstract

Background—Although numerous antibodies suitable for use on paraffin wax embedded sections are available for the subtyping of acute leukaemia (acute myelogenous leukaemia (AML) and acute lymphoblastic leukaemia (ALL)) in bone marrow biopsy sections, unequivocal identification of the cell line involved is sometimes impossible.

Methods—Forty eight formalin fixed, paraffin wax embedded bone marrow biopsy specimens that had been decalcified in EDTA were investigated, including 42 thought to exhibit ALL on the basis of bone marrow smears. Five specimens exhibited AML and one biphenotypic leukaemia, as diagnosed immunohistochemically in bone marrow biopsies. Immunostaining was performed with antibodies against relatively specific B and T cell antigens. The blasts were investigated for rearrangements of the immunoglobulin heavy chain (IgH) and the T cell antigen receptor (TCR) genes.

Results—Amplifiable DNA was obtained from all 48 specimens. An IgH gene rearrangement was detected in 20 of 23 c-ALL specimens. Four of seven T cell ALL (T-ALL) specimens had a TCR- γ gene rearrangement, and the one B cell ALL (B-ALL) specimen exhibited a clonal IgH gene. Three of four cases of unclassifiable ALL could be assigned to the B cell lineage on the basis of gene rearrangement analysis. Seven cases originally diagnosed in smears as ALL were rediagnosed as AML (n = 5) or biphenotypic leukaemia (n = 2) because of immunohistochemical reactivity for myeloperoxidase or lysozyme. Two of these AML cases and two of three cases of biphenotypic leukaemia exhibited a monoclonal IgH gene rearrangement.

Conclusions—Acute leukaemia can be subtyped in bone marrow sections with a limited panel of antibodies suitable for use on paraffin wax embedded sections (against CD3, CD10, CD20, CD79a, myeloperoxidase, and lysozyme). In patients with ALL and a diagnostically equivocal immunophenotype, gene rearrangement analysis might indicate whether the B or T cell lineage is involved.

Keywords: acute lymphoblastic leukaemia; immunohistochemistry; polymerase chain reaction

The term acute lymphoblastic leukaemia (ALL) describes a heterogeneous group of acute leukaemias that usually manifest themselves primarily in the bone marrow and blood as a neoplastic proliferation of lymphoblasts. It is usually possible to subtype ALL in sections of bone marrow biopsy specimens (taken from the iliac crest) using immunohistochemical techniques.¹ A particularly large panel of antibodies that can be used on paraffin wax embedded tissue is necessary when the lymphoblasts have unusual immunophenotypes.

However, in a few cases, definitive immunohistochemical identification of the lineage (B or T cell) is not possible. We have tried to solve this problem by using the polymerase chain reaction (PCR). The lineage of lymphoid cells can be identified by investigations to detect rearrangement of the immunoglobulin heavy chain (IgH) and/or T cell antigen receptor (TCR) genes.²⁻⁶ Unlike Southern blotting, the PCR method can be used on very small, formalin fixed, paraffin wax embedded specimens.

We assessed the diagnostic value of gene rearrangement analysis in ALL using a large series of patients with acute leukaemia from our department, and with particular reference to those in which the tumour cell lineage could not be identified with certainty by immunostaining.

Material and methods

A total of 42 bone marrow biopsy specimens shown by cytomorphological, enzyme cytochemical, and immunocytochemical investigations to contain infiltrates of ALL were included in our study (all cases included in a previous study).¹ Five cases of acute myelogenous leukaemia (AML) and one of mixed myelogenous/lymphoblastic (biphenotypic) leukaemia, all of which had been diagnosed immunohistochemically, served as controls. All the specimens were fixed in 5% buffered formalin, mildly decalcified in EDTA,^{7,8} and embedded in paraffin wax. Serial sections were cut at 4 μ m and stained with haematoxylin and eosin, Giemsa, the periodic acid-Schiff reaction, and the naphthol AS-D chloroacetate esterase reaction. Immunohistochemical staining was performed by the avidin-biotin-peroxidase complex method.⁹ Although a very

Institute of Pathology,
University of
Tübingen, D-72076
Tübingen, Germany
S M Kröber
A Greschniok
E Kaiserling
H-P Horny

Correspondence to:
Dr Kröber, Institut für
Pathologie,
Eberhard-Karls-Universität,
Liebermeisterstrasse 8,
D-72076 Tübingen,
Germany
email:
stefan-martin.kroeber@
med.uni-tuebingen.de

Accepted for publication
25 January 2000

broad panel of antibodies was used, particular emphasis in the evaluation was placed on those antibodies with high lineage specificity; that is, those antibodies directed against: myeloperoxidase (MPO; Dako, Hamburg, Germany), lysozyme (Lys; Dako), terminal deoxynucleotidyl transferase (TdT; Dako), CD3 (Novocastria, Newcastle upon Tyne, UK), CD10 (Novocastria), CD20 (Dako), CD79a (Dako), and β F1 (β chain of TCR; T-cell Diagnostics Inc, Cambridge, UK).¹

Immunostaining gave definite confirmation of the diagnosis of ALL in 35 cases: c-ALL (n = 23), T cell ALL (T-ALL; n = 7), B cell ALL (B-ALL; n = 1), and u-ALL (not classifiable; n = 4) (table 1). Seven cases that had originally been diagnosed in smears as ALL were shown by staining with antibodies against myeloperoxidase and lysozyme to be either myeloid leukaemia (AML-M1, n = 2; AML-M4, n = 2; and AML-M5, n = 1) or biphenotypic leukaemia (n = 2). Together with the control cases, this made a total of 12 cases of AML and three cases of biphenotypic leukaemia.

The PCR investigations for IgH and TCR- γ gene rearrangements were performed according to a standardised protocol.¹⁰ DNA extracts from a lymph node with diffuse infiltration by B cell chronic lymphoblastic leukaemia (B-CLL) and a large cell anaplastic T cell lymphoma were used as positive controls.

Results

Amplifiable DNA was extracted from all 48 bone marrow specimens. Monoclonal or polyclonal PCR products of the IgH and TCR- γ gene rearrangements could be identified in all the 35 cases of ALL that could be analysed by PCR (that is, β globin positive cases). Table 1 gives a summary of the molecular biological findings and diagnostically relevant immunohistochemical findings with highly lineage specific antibodies.

Monoclonal IgH rearrangement patterns were found in 20 of the 23 cases of c-ALL (fig 1). One specimen (case 8), with the immunophenotype TdT positive, CD10 positive, CD79a positive, exhibited monoclonal rearrangements of both the IgH gene and the TCR- γ gene. A further c-ALL case had

Table 1 Immunophenotype, clonality, and subtype of the cases of acute leukaemia investigated

No.	Immunoreactivity				Monoclonality		Primary diagnosis	Probable lineage on the basis of PCR
	MPO/Lys	TdT	CD10/CD20/CD79a	CD3/ β F1	IgH	TCR- γ		
1			CD10/CD20		+		c-ALL	
2			CD10/CD20	β F1	+		c-ALL	
3			CD10		+		c-ALL	
4		TdT	CD10		+		c-ALL	
5		TdT	CD10/CD79a		+		c-ALL	
6		TdT	CD10/CD79a	β F1	+		c-ALL	
7		TdT	CD10	β F1	+		c-ALL	
8		TdT	CD10/CD79a		+	+	c-ALL	ALL, bilinear genotype?
9		TdT	CD10/CD20		+		c-ALL	
10		TdT	CD10/CD79a	CD3	+		c-ALL	
11		TdT	CD10/CD79a		+		c-ALL	
12		TdT	CD10/CD20		+		c-ALL	
13		TdT	CD10/CD79a		+		c-ALL	
14		TdT	CD10/CD79a		+		c-ALL	
15		TdT	CD10/CD79a		+		c-ALL	
16		TdT	CD10/CD79a		+		c-ALL	
17			CD10/CD20		+		c-ALL	
18		TdT	CD10			+	c-ALL	T-ALL
19			CD10	CD3/ β F1			c-ALL	
20		TdT	CD10/CD20/CD79a	β F1	+		c-ALL	
21		TdT	CD10/CD79a		+		c-ALL	
22		TdT	CD10		+		c-ALL	
23		TdT	CD10/CD79a		+		c-ALL	
24				CD3/ β F1		+	T-ALL	
25		TdT		β F1		+	T-ALL	
26		TdT		CD3			T-ALL	
27		TdT		β F1			T-ALL	
28		TdT		β F1		+	T-ALL	
29						+	T-ALL	
30		TdT		β F1	+		T-ALL	ALL, B cell genotype?
31			CD20/CD79a		+		B-ALL	
32			CD20/CD79a	CD3	+		u-ALL	ALL, B cell genotype
33					+		u-ALL	ALL, B cell genotype
34			CD20		+		u-ALL	ALL, B cell genotype
35		TdT			+	+	u-ALL	ALL, bilinear genotype
36	MPO	TdT			+		AL, biphenotypic	
37	MPO		CD20	β F1			AL, biphenotypic	
38	MPO	TdT	CD79a		+		AL, biphenotypic	B cell type
39	MPO				+		AML-M1	B cell genotype?
40	MPO						AML-M1	
41	MPO						AML-M1	
42	MPO						AML-M1	
43	MPO/Lys						AML-M4	
44	MPO/Lys						AML-M4	
45	MPO						AML-M4	
46	MPO						AML-M4	
47	MPO						AML-M4	
48	MPO/Lys				+		AML-M5	B-cell genotype ?

Cases were recorded as immunoreactive if more than 10% of the blast cells were positive. AL, acute leukaemia; ALL, acute lymphoblastic leukaemia; AML, acute myelogenous leukaemia; B-ALL, B cell ALL; IgH, immunoglobulin heavy chain; MPO, myeloperoxidase; Lys, lysozyme; PCR, polymerase chain reaction; T-ALL, T cell ALL; TCR- γ , T cell receptor γ ; TdT, terminal deoxynucleotidyl transferase; u-ALL, unclassified ALL.

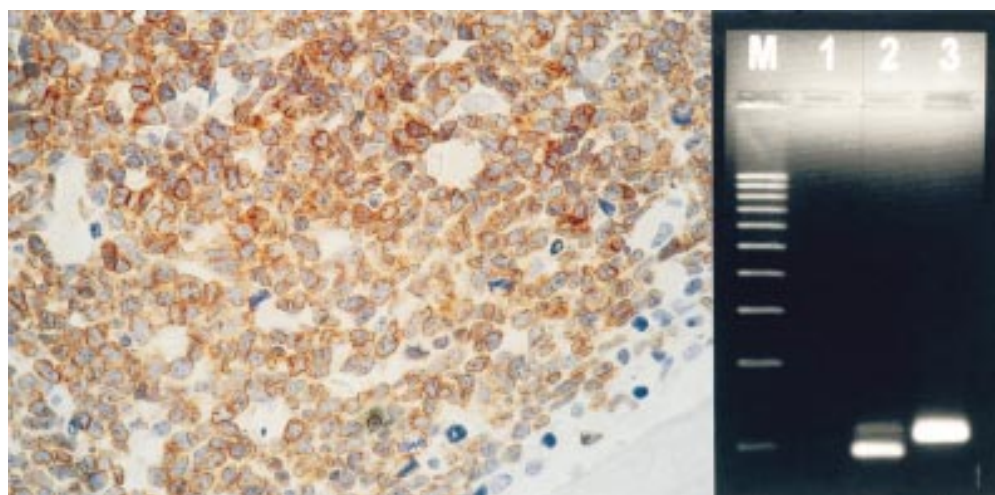


Figure 1 Trephine biopsy specimen taken from the iliac crest of a patient with acute lymphoblastic leukaemia (c-ALL; case 6). Left: extremely hypercellular marrow with subtotal depletion of fat cells and normal blood cell precursors. Most of the cells are reactive for the B cell associated antigen CD79a. Note the pronounced membrane associated ("annular") immunostaining, which indicates that the staining is specific. Avidin–biotin–peroxidase complex (ABC) method, anti-CD79a. Right: ethidium bromide stained agarose gel showing PCR analysis of the immunoglobulin heavy chain (IgH) gene rearrangements in complementarity determining region 3 (CDR3). Note the clear monoclonal band of lane 3 (case 6). M, molecular weight markers (100 bp ladder); lane 1, no DNA; lane 2, case 31; lane 3, case 6.

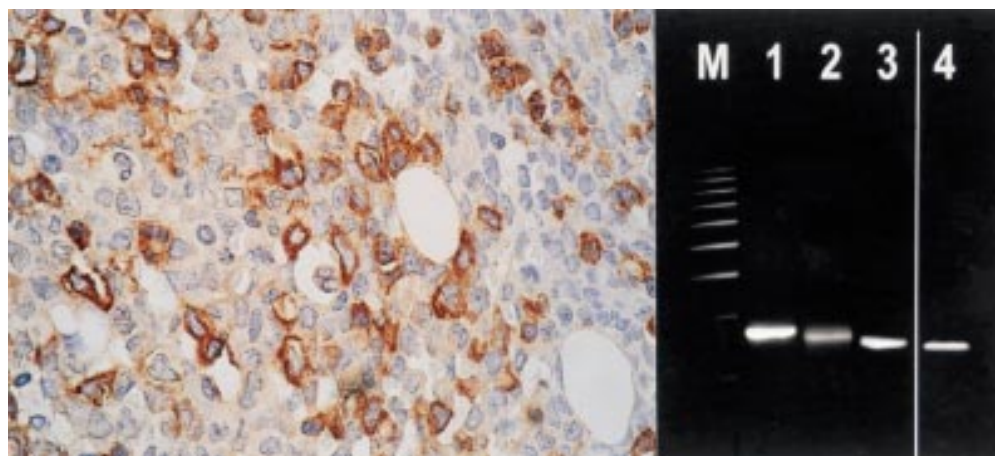


Figure 2 Trephine biopsy specimen taken from the iliac crest of a patient with biphenotypic acute leukaemia (case 38). Left: hypercellular marrow infiltrated by blast cells, almost all of which are reactive for myeloperoxidase (MPO). In addition, most of the blast cells were also immunoreactive for CD79a and terminal deoxynucleotidyl transferase (TdT) (not shown). Right: ethidium bromide stained agarose gel showing PCR analysis of the immunoglobulin heavy chain (IgH) gene rearrangements in complementarity determining region 2 (CDR2). Note the clear monoclonal band of lane 4 (case 38). M, molecular weight markers (100 bp ladder); lane 1, case 5; lane 2, case 11; lane 3, case 17; lane 4, case 38.

monoclonal rearrangement of only the TCR- γ gene; the immunophenotype of the blasts here was TdT positive, CD10 positive (case 18). Among the seven cases of T-ALL, monoclonal rearrangement of the TCR- γ gene was found in four, and of the IgH gene in one. The TCR- γ rearrangement was polyclonal in the latter case (case 30) and the blast cells expressed TdT and β F1. As expected, the one case of B-ALL (case

31) exhibited a monoclonal rearrangement of the IgH gene. A monoclonal rearrangement of the IgH gene was found in all four cases of u-ALL; one of these (case 35), which was immunoreactive only for TdT, also exhibited a monoclonal rearrangement of the TCR- γ gene.

A monoclonal IgH gene rearrangement pattern was found in two of the three cases of biphenotypic leukaemia (cases 36 and 38; fig 2) and in two of the 10 cases diagnosed as AML on the basis of the immunohistochemical findings (cases 39 and 48). None of the AML cases exhibited a monoclonal TCR- γ gene.

In summary, the diagnosis of ALL and the subtype identified were confirmed by PCR in 25 of the 31 cases (table 2). It was possible to classify three of the four cases of u-ALL as deriving from the B cell lineage. Two of the three cases of biphenotypic leukaemia exhibited a monoclonal rearrangement of the IgH gene.

Table 2 Molecular biological findings in relation to the leukaemia subtype

Immunohistochemical diagnosis	Number of cases	Monoclonal rearrangement	%
B-ALL	n = 1	1 (IgH)	100
T-ALL	n = 7	5 (4 TCR- γ , 1 IgH)	71
c-ALL	n = 23	21 (19 IgH, 1 IgH + TCR- γ , 1 TCR- γ)	91
u-ALL	n = 4	4 (3 IgH, 1 IgH + TCR- γ)	100
ALL	n = 35	31 (26 IgH, 7 TCR- γ)	89
AL, biphenotypic	n = 3	2 (IgH)	67
AML	n = 10	2 (IgH)	20

AL, acute leukaemia; ALL, acute lymphoblastic leukaemia; AML, acute myelogenous leukaemia; B-ALL, B cell ALL; IgH, immunoglobulin heavy chain; T-ALL, T cell ALL; TCR- γ , T cell receptor γ ; u-ALL, unclassified ALL.

Discussion

The most commonly used systems of classification of acute leukaemia are based mainly on cytomorphological, enzyme cytochemical, and immunocytochemical findings in blood and bone marrow smears. If bone marrow aspiration is unsuccessful, the investigation of bone marrow biopsy specimens (from the iliac crest) becomes of major diagnostic importance.

Various investigators have studied the diagnostic value of antibodies suitable for use on paraffin wax embedded sections in the diagnosis of acute leukaemia in sections from bone marrow biopsy specimens,¹¹⁻¹⁶ and the following panel is generally considered suitable for subtyping in this situation: MPO, TdT, lysozyme, CD3, CD10, CD79a, CD20, and β F1.¹ The new WHO classification system of the acute leukaemias is based on a revision of the French-American-British (FAB) system, and takes particular account of cytogenetic and molecular genetic findings, especially in the case of ALL.¹⁷⁻¹⁹ Therefore, we investigated the diagnostic value of molecular biological rearrangement analysis in acute leukaemia, particularly in cases in which routine investigation of bone marrow biopsy specimens had not revealed a diagnostically unequivocal immunophenotype.

The finding of a high proportion of cases with monoclonal rearrangement patterns (> 80%) was surprising, because immature neoplasms of the lymphoid lineage (and therefore ALL) are thought to exhibit false negative findings concerning monoclonality in many cases.^{2-20, 21} However, analysis of unfixed cells from bone marrow aspirates in ALL has revealed informative IgH gene rearrangements in up to 95% of cases and TCR- γ or TCR- δ rearrangements in up to 84% of cases.^{22, 23}

Gene analysis is based on a comparative PCR. The main source of error of a false positive result is therefore unsuitably small numbers of cells from which the DNA has been extracted.²⁴ The rearranged VDJ sequences of the template DNA of any given cells (including non-neoplastic cells) can bind preferentially to the PCR primers.²⁵ However, in our study, the clonality of the IgH and TCR- γ gene rearrangements was determined in all cases in DNA extracts from iliac crest bone marrow biopsy specimens with diffuse, compact infiltration by blasts. It can therefore be assumed that the cell numbers here were adequate.

Only cases that had been diagnosed as ALL on the basis of blood and bone marrow smears were included in our study. The PCR findings in the one B-ALL case and in four of the seven T-ALL cases confirmed the lineage identified by the immunohistochemical investigation of bone marrow biopsy specimens. False negative findings of gene analysis can be expected more often in T cell neoplasms than in B cell neoplasms because the method is less sensitive and these neoplasms sometimes exhibit a germ line configuration—that is, non-rearranged configuration of the TCR gene—despite CD3 positivity.^{26, 27} As expected, a monoclonal IgH gene rearrangement was found in most (19 of 23) cases of c-ALL, confirming that they are

indeed B cell in origin. The molecular biological findings were of particular interest in the four cases that remained unclassifiable on the basis of the immunohistochemical findings, that is, cases of u-ALL. In three of these four cases, the finding of a monoclonal IgH rearrangement showed the blasts to be of B cell origin. This suggests that in cases where the lineage of a TdT positive leukaemia cannot be identified by immunohistochemical investigation, molecular genetic analysis can be of major diagnostic value.

Six control cases were included to test the specificity of the method: five AML cases and one case of biphenotypic leukaemia, all diagnosed immunohistochemically. Therefore, a total of 13 cases of AML and biphenotypic leukaemia was investigated. In two of the biphenotypic leukaemias, at least some of the blasts were found to be of B cell origin by the identification of a monoclonal IgH gene rearrangement. In one of these, immunohistochemical investigation revealed about 20% of the blasts to be CD79a positive, a finding that supports the diagnosis of mixed leukaemia, with one blast cell population with a myeloid phenotype, and one blast cell population with a B cell genotype.

Among the cases with a definite myeloid immunophenotype were two in which the molecular biological finding of a monoclonal IgH rearrangement was inconsistent. In one of these, a case of AML-M1, almost 100% of the blasts were found to express MPO, and CD20 positive B lymphocytes accounted for far less than 10% of the cells. In the other case, a case of AML-M5 with a monoclonal IgH rearrangement, more than 90% of the blast cells were positive for lysozyme and, again, few CD20 positive B lymphocytes were identified by immunohistochemical staining. The inconsistency between the immunohistochemical and molecular biological findings might have been caused by a false positive PCR result deriving from a sampling error, as can occur in very lymphocyte depleted or microdissected tissue.^{24, 28, 29} The finding of a monoclonal IgH gene rearrangement could also result from an aberrant recombination of the IgH gene in the tumour cells with a myeloid immunophenotype,^{27, 30, 31} but it was not possible to determine whether this was the case with the method used here. It can only be concluded from our investigations and the criteria of the WHO classification system that a diagnosis of biphenotypic leukaemia should be reserved for cases in which the cytogenetic and molecular biological findings indicate transformation of a stem cell with differentiation towards the lymphoid and myeloid cell lines.¹⁹

Inconsistencies between the immunohistochemical and molecular biological findings were also noted in a relatively small proportion of the ALL cases with lymphoid differentiation alone (four of 35). In one case of T-ALL with TdT positive and β F1 positive blasts, there was a monoclonal IgH gene rearrangement and a polyclonal TCR- γ gene rearrangement, although the blasts expressed none of the B cell markers investigated. It is not possible to say

with certainty whether this represented an ALL with bilinear differentiation; that is, a T cell associated immunophenotype with a B cell associated IgH rearrangement, because such illegitimate IgH rearrangements are said to be extremely rare.³² Only occasional cases of IgH monoclonal T cell neoplasms and TCR monoclonal B cell neoplasms have been described.^{26 33-35} Coexistent monoclonal IgH and TCR gene rearrangements, as in bilinear lymphoblastic leukaemia, have been found relatively often in unfixed bone marrow aspirates, and monoclonal TCR rearrangements have been reported to have a relatively high incidence in both B-ALL and T-ALL.^{23 36 37} A further case with a genotype/phenotype discrepancy was an IgH monoclonal c-ALL that also exhibited a TCR- γ gene rearrangement. However, the lymphoblasts in this case expressed only B cell markers, such as CD10 and CD79a. No T cell antigens were detected, although it must be said that not all the relevant markers (especially CD7) would have been detected by the panel of antibodies used. These two last cases exhibited findings consistent with the diagnoses of ALL with B cell genotype and ALL with bilinear genotype. One case of c-ALL exhibited a monoclonal TCR- γ gene rearrangement and a polyclonal IgH gene rearrangement. More than 50% of the blasts in this case expressed OPD4, a T helper cell associated marker.¹ These findings led us to amend the diagnosis to T-ALL.

In conclusion, from our findings and published data it appears that the most suitable approach to the diagnosis of acute leukaemia is the evaluation of a bone marrow biopsy, as well as blood and bone marrow smears, by enzyme cytochemical and immunohistochemical techniques. In cases of ALL with a diagnostically equivocal immunophenotype, it is usually possible to determine the lineage (B or T cell) by molecular biological analysis.

The authors are grateful to Ms H Ableiter and Ms A Mall for excellent technical assistance, Dr B Toth for help in assessing immunohistochemical data, and Dr M Ruck for translation of the manuscript. Thanks also to Dako Diagnostica GmbH, Hamburg, Germany for contributing towards the reproduction costs of the colour artwork.

- Toth B, Wehrmann M, Kaiserling E, et al. Immunophenotyping of acute lymphoblastic leukaemia (ALL) in routinely-processed bone marrow biopsy specimens. *J Clin Pathol* 1999;52:688-92.
- Arnold A, Cossman J, Bakhshi A, et al. Immunoglobulin gene rearrangements as unique clonal markers in human lymphoid neoplasms. *N Engl J Med* 1983;309:1593-9.
- Cossman J, Zehnauer B, Garrett CT, et al. Gene rearrangements in the diagnosis of lymphoma/leukemia. Guidelines for use based on a multiinstitutional study. *Am J Clin Pathol* 1991;95:347-54.
- Griesser H. Gene rearrangements and chromosomal translocations in T cell lymphoma—diagnostic applications and their limits. *Virchows Arch* 1995;6:323-38.
- Voena C, Ladetto M, Astolfi M, et al. A novel nested-PCR strategy for the detection of rearranged immunoglobulin heavy-chain genes in B cell tumors. *Leukemia* 1997;11:1793-8.
- Pillozzi E, Muller-Hermelink HK, Falini B, et al. Gene rearrangements in T-cell lymphoblastic lymphoma. *J Pathol* 1999;188:267-70.
- Horny HP, Kaiserling E. Lymphoid cells and tissue mast cells of bone marrow lesions in systemic mastocytosis: a histological and immunohistological study. *Br J Haematol* 1988;69:449-55.
- Horny HP, Engst U, Walz RS, et al. In situ immunophenotyping of lymphocytes in human bone marrow: an immunohistochemical study. *Br J Haematol* 1989;71:313-21.
- Hsu S, Raine L, Fanger H. Use of avidin-biotin-peroxidase complex (ABC) in immunoperoxidase techniques: a comparison between ABC and unlabeled antibody (PAP) procedures. *J Histochem Cytochem* 1981;29:577-80.
- Kröber SM, Horny HP, Greschniok A, et al. Reactive and neoplastic lymphocytes in human bone marrow. Morphological, immunohistological and molecular biological investigations on biopsy specimens. *J Clin Pathol* 1999;52:521-6.
- Horny HP, Campbell M, Steinke B, et al. Acute myeloid leukemia: immunohistologic findings in paraffin-embedded bone marrow biopsy specimens. *Hum Pathol* 1990;21:648-55.
- Kurec AS, Cruz VE, Barrett D. Immunophenotyping of acute leukemias using paraffin-embedded tissue sections. *Am J Clin Pathol* 1990;93:502-9.
- Perkins SL, Kjeldsberg CR. Immunophenotyping of lymphomas and leukemias in paraffin-embedded tissues. *Am J Clin Pathol* 1993;99:362-73.
- Horny HP, Wehrmann M, Steinke B, et al. Assessment of the value of immunohistochemistry in the subtyping of acute leukemia on routinely processed bone marrow biopsy specimens with particular reference to macrophage-associated antibodies. *Hum Pathol* 1994;25:810-14.
- Rousselet MC, Laniece A, Gardais J, et al. Immunohistochemical characterization of acute leukemia. Study of 31 bone marrow biopsies. *Ann Pathol* 1995;15:119-26.
- Chuang SS, Li CY. Useful panel of antibodies for the classification of acute leukemia by immunohistochemical methods in bone marrow trephine biopsy specimens. *Am J Clin Pathol* 1997;107:410-18.
- Pui CH, Campana D, Crist WM. Toward a clinically useful classification of the acute leukemias. *Leukemia* 1995;9:2154-7.
- Bloomfield CD, Herzig GP, Caligiuri MA. Introduction: acute leukemia: recent advances. *Semin Oncol* 1997;24:1-2.
- Willman CL. Acute leukemias: a paradigm for the integration of new technologies in diagnosis and classification. *Mod Pathol* 1999;12:218-28.
- Deane M, Norton JD. Detection of immunoglobulin gene rearrangement in B lymphoid malignancies by polymerase chain reaction gene amplification. *Br J Haematol* 1990;74:251-6.
- Deane M, McCarthy KP, Wiedemann LM, et al. An improved method for detection of B-lymphoid clonality by polymerase chain reaction. *Leukemia* 1991;5:726-30.
- Potter MN, Cross NCP, van Dongen JJM, et al. Molecular evidence of minimal residual disease after treatment for leukaemia and lymphoma: an updated meeting report and review. *Leukemia* 1993;7:1302-14.
- Cavé H, van der Werff Ten Bosch J, Suciu S, et al. Clinical significance of minimal residual disease in childhood acute lymphoblastic leukemia. *N Engl J Med* 1998;339:591-8.
- Zhou XG, Sandvej K, Gregersen N, et al. Detection of clonal B cells in microdissected reactive lymphoproliferations: possible diagnostic pitfalls in PCR analysis of immunoglobulin heavy chain gene rearrangement. *J Clin Pathol: Mol Pathol* 1999;52:104-10.
- Corradini P, Boccadoro M, Pileri A. Analysis of immunoglobulin heavy chain gene rearrangement using the polymerase chain reaction. *Blood* 1992;79:291-2.
- Chen YT, Godwin TA, Mouradian JA. Immunohistochemistry and gene rearrangement studies in the diagnosis of malignant lymphomas: a comparison of 152 cases. *Hum Pathol* 1991;22:1249-57.
- Casares S, Rodriguez JM, Martin A, et al. T-cell receptor gene rearrangements in lymphoid and non-lymphoid leukaemias. *Eur J Clin Invest* 1994;24:119-25.
- Wan JH, Sykes PJ, Orell SR, et al. Rapid method for detecting monoclonality in B cell lymphoma in lymph node aspirates using the polymerase chain reaction. *J Clin Pathol* 1992;45:420-3.
- Pan LX, Diss TC, Peng HZ, et al. Clonality analysis of defined B-cell populations in archival tissue sections using microdissection and the polymerase chain reaction. *Histopathology* 1994;24:323-7.
- Rovigatti U, Mirro J, Kitchingman G, et al. Heavy chain immunoglobulin gene rearrangement in acute nonlymphocytic leukemia. *Blood* 1984;63:1023-7.
- Greaves-MF, Chan-LC, Furlley-AJ, et al. Lineage promiscuity in hemopoietic differentiation and leukemia. *Blood* 1986;67:1-11.
- Ha-Kawa K, Hara J, Keiko Y, et al. Kappa-chain gene rearrangement in an apparent T-lineage lymphoma. *J Clin Invest* 1986;78:1439-42.
- Korsmeyer SJ, Arnold A, Bakhshi A, et al. Immunoglobulin gene rearrangement and cell surface antigen expression in acute lymphocytic leukemias of T cell and B cell precursor origins. *J Clin Invest* 1983;71:301-13.
- Kitchingman GR, Rovigatti U, Mauer AM, et al. Rearrangement of immunoglobulin heavy chain genes in T cell acute lymphoblastic leukemia. *Blood* 1985;65:725-9.
- Cleary ML, Chao J, Warnke R, et al. Immunoglobulin gene rearrangement as a diagnostic criterion of B-cell lymphoma. *Proc Natl Acad Sci U S A* 1984;81:593-7.
- Breit TM, Wolvers-Tettero IL, Beishuizen A, et al. Southern blot patterns, frequencies, and junctional diversity of T-cell receptor-delta gene rearrangements in acute lymphoblastic leukemia. *Blood* 1993;82:3063-74.
- Szczepanski T, Beishuizen A, Pongers-Willems MJ, et al. Cross-lineage T cell receptor gene rearrangements occur in more than ninety percent of childhood precursor-B acute lymphoblastic leukemias: alternative PCR targets for detection of minimal residual disease. *Leukemia* 1999;13:196-205.



Acute lymphoblastic leukaemia: correlation between morphological/immunohistochemical and molecular biological findings in bone marrow biopsy specimens

S M Kröber, A Greschniok, E Kaiserling, et al.

Mol Path 2000 53: 83-87
doi: 10.1136/mp.53.2.83

Updated information and services can be found at:
<http://mp.bmj.com/content/53/2/83.full.html>

References

These include:

This article cites 34 articles, 11 of which can be accessed free at:
<http://mp.bmj.com/content/53/2/83.full.html#ref-list-1>

Article cited in:
<http://mp.bmj.com/content/53/2/83.full.html#related-urls>

Email alerting service

Receive free email alerts when new articles cite this article. Sign up in the box at the top right corner of the online article.

Notes

To request permissions go to:
<http://group.bmj.com/group/rights-licensing/permissions>

To order reprints go to:
<http://journals.bmj.com/cgi/reprintform>

To subscribe to BMJ go to:
<http://group.bmj.com/subscribe/>