

# Expression of $\pi$ -class glutathione S-transferase: two populations of high grade prostatic intraepithelial neoplasia with different relations to carcinoma

R Montironi, R Mazzucchelli, D Stramazotti, R Pomante, D Thompson, P H Bartels

## Abstract

**Background/Aims**—Patients with high grade prostatic intraepithelial neoplasia of the transition zone appear to be at increased risk of developing prostatic carcinoma, although not to the same degree as patients with high grade prostatic intraepithelial neoplasia of the peripheral/central zone. Previous investigations have shown loss of expression of  $\pi$ -class glutathione S-transferase (GST- $\pi$ ; an enzyme that protects against electrophilic carcinogens) in prostatic carcinoma and in high grade prostatic intraepithelial neoplasia. The aim of this study was to compare the expression of GST- $\pi$  in high grade prostatic intraepithelial neoplasia of the transition zone with that in high grade prostatic intraepithelial neoplasia of the peripheral/central zone (that is, non-transition zone).

**Methods**—Immunostaining with the anti-GST- $\pi$  antibody was performed on 20 high grade prostatic intraepithelial neoplasia samples of the transition zone, either isolated or associated with prostatic carcinoma (groups 1 and 2, respectively; 10 cases each) and on 20 high grade prostatic intraepithelial neoplasia samples of the non-transition zone, either isolated or associated with prostatic carcinoma (groups 3 and 4, respectively; 10 cases each). This study also included six samples of high grade prostatic intraepithelial neoplasia simultaneously present in the transition and non-transition zones and not associated with prostatic carcinoma (group 5). The presence of immunostaining, staining intensity, and the distribution of immunostaining were evaluated in the high grade prostatic intraepithelial neoplasia lesions and in the normal tissue and cancer areas.

**Results**—The GST- $\pi$  antibody stained the cytoplasm of the cells lining the ducts and acini of normal prostate tissue. Staining was stronger and more diffuse in the basal cell layer than in the luminal (or secretory) cell layer. Immunohistochemical staining with anti-GST- $\pi$  antibodies failed to detect the enzyme in all prostatic carcinoma foci but one. Two patterns were detected in high grade prostatic intraepithelial neoplasia. One was represented by GST- $\pi$  staining similar to that of the normal tissue (pattern A). The other devi-

ated from it and was characterised by absence of GST- $\pi$  expression in the secretory cells and abundant expression in scattered basal cells (pattern B). Pattern A staining was seen more frequently in the transition than in the non-transition zone. Pattern B staining was seen mainly in high grade prostatic intraepithelial neoplasia of non-transition zone associated with cancer.

**Conclusions**—The differential expression of GST- $\pi$  in the transition and non-transition zones indicates the existence of two populations with the morphological appearance of high grade prostatic intraepithelial neoplasia that might have different associations with carcinoma.

(J Clin Pathol: Mol Pathol 2000;53:122-128)

Keywords: prostate; prostatic intraepithelial neoplasia; prostatic adenocarcinoma;  $\pi$ -class glutathione S-transferase; methylation

Prostatic intraepithelial neoplasia is an abnormality of the prostatic epithelium thought to be the precursor lesion of prostate cancer.<sup>1-4</sup> From the morphological point of view, prostatic intraepithelial neoplasia is characterised by ducts and acini with cytological atypia of the secretory cells, and with a basal cell layer still recognisable. This lesion encompasses a spectrum of morphological changes in the luminal cells, ranging from low grade to high grade prostatic intraepithelial neoplasia.<sup>1</sup> High grade prostatic intraepithelial neoplasia usually arises in the peripheral zone of the prostate, the area in which most (70%) prostatic cancers occur, and both are frequently multifocal, indicating a "field" effect. Evidence supporting an association between high grade prostatic intraepithelial neoplasia and prostatic carcinoma has been found in histological, immunohistochemical, morphometric, and genetic studies.<sup>1 2 5</sup> High grade prostatic intraepithelial neoplasia, when found alone on prostate biopsy, is associated with a 50% risk of detection of prostatic carcinoma of the peripheral zone on subsequent biopsy.<sup>5</sup> High grade prostatic intraepithelial neoplasia is relatively uncommon in the transition zone, as determined on transurethral resection of the prostate specimens.<sup>6 7</sup> High grade prostatic intraepithelial neoplasia coexisting with cancer in resection specimens is seen in 10% of cases.<sup>6</sup>

The glutathione S-transferases (GSTs) are a family of multifunctional isoenzymes that

Institute of  
Pathological Anatomy  
and Histopathology,  
University of Ancona,  
I-60020 Torrette,  
Ancona, Italy  
R Montironi  
R Mazzucchelli  
D Stramazotti  
R Pomante

Optical Sciences  
Center, University of  
Arizona, Tucson, 85721  
Arizona, USA  
D Thompson  
P H Bartels

Correspondence to:  
Professor Montironi,  
Institute of Pathological  
Anatomy and  
Histopathology, University of  
Ancona School of Medicine,  
Ospedale Regionale, I-60020  
Torrette, Ancona, Italy  
email: r.montironi@  
popcsi.unian.it

Accepted for publication  
3 March 2000

catalyse the nucleophilic addition of glutathione to a heterogeneous group of compounds.<sup>8</sup> GST isoenzymes can be characterised on the basis of substrate specificity, sensitivity to inhibitors, isoelectric points, immunological crossreactivity, and amino acid composition and sequence. A variety of biological functions have been ascribed to this enzyme group, including intracellular binding and transport of lipophilic compounds such as bile products, steroid hormones, drugs, and xenobiotics. By far the most studied function of the GST enzymes is their role in cellular detoxification,<sup>9</sup> primarily against oxygen free radicals and peroxides produced by cellular physiological processes and exogenous stimuli. GSTs might prevent carcinogenesis through inactivation of reactive electrophiles by conjugation to reduced glutathione.<sup>10</sup> Human GSTs have been classified into five families:  $\alpha$ ,  $\mu$ ,  $\theta$ ,  $\pi$ , and microsomal.<sup>11</sup> The most widely investigated with respect to human malignancy is GST- $\pi$ .<sup>12-25</sup>

Loss of expression of GST- $\pi$  has been shown in prostatic carcinoma and in high grade prostatic intraepithelial neoplasia.<sup>26-33</sup> This finding supports a role for high grade prostatic intraepithelial neoplasia as a precursor lesion, and might provide insight into the molecular pathogenesis of prostate cancer. To the best of our knowledge there are no previous studies evaluating the expression of this enzyme in prostatic intraepithelial neoplasia from the different prostate zones.

The aim of our study was to compare the immunohistochemical expression of GST- $\pi$  in prostatic intraepithelial neoplasia of the transition zone with that of the non-transition zone. Because high grade prostatic intraepithelial neoplasia is more closely correlated with prostatic carcinoma than the low grade form, and thus more likely to represent a proximate precursor lesion, we focused on high grade prostatic intraepithelial neoplasia for the evaluation of GST- $\pi$  expression.<sup>34</sup>

## Materials and methods

### TISSUE SAMPLES

Forty six prostatectomy specimens from patients with high grade prostatic intraepithelial neoplasia were included in our study. None of the patients had received chemotherapy, hormone treatment, or radiotherapy before surgery. The material had been processed at the institute of pathological anatomy and histopathology of the University of Ancona School of Medicine. Briefly, simple and radical prostatectomy specimens had been covered with India ink and fixed for 24 hours in neutral buffered formalin (4%). To enhance a quick and uniform penetration of the fixative, prostate specimens were injected with formalin solution. The rationale behind the injection procedure was that, during immersion in a formalin solution, the fixative diffuses very slowly towards the centre of the specimens. When the periphery of the prostate is fixed, the presence of crosslinked proteins is thought to hinder further diffusion of the fixative toward the centre of the specimen (so called crust effect). After fixation, the prostate specimens had been step sectioned at 0.4 cm intervals perpendicular to the long axis (apical-basal) of the gland. The distal (apical) and proximal (basal) parts of the prostates and the seminal vesicles had been removed from the radical prostatectomy specimens and submitted for histological examination. The cut specimens had been post-fixed for an additional 24 hours and then dehydrated in graded alcohols, cleared in xylene, embedded in paraffin wax, and examined histologically as 5  $\mu$ m thick whole mount sections.

The samples were selected to represent the following five groups (the age of the patients in all the groups was comparable and ranged from 60 to 70 years): high grade prostatic intraepithelial neoplasia samples of the transition zone, either isolated or associated with prostatic carcinoma (groups 1 and 2, respectively; 10 cases for each group); high grade prostatic intraepithelial neoplasia samples of the non-transition zone, either isolated or associated with prostatic carcinoma (groups 3 and 4, respectively; 10 cases for each group); and samples of high grade prostatic intraepithelial neoplasia simultaneously present in the transition and non-transition zones (group 5; six cases) (table 1). The following criteria were adopted in the identification of high grade prostatic intraepithelial neoplasia<sup>1-3</sup>: crowding and stratification of the secretory cells with cytological changes mimicking cancer, including enlargement of nuclei and presence of prominent nucleoli, the latter often being multiple and eccentrically positioned. The basal cell layer at the periphery has to be recognisable. In each case, the slide with the largest focus of high grade prostatic intraepithelial neoplasia was selected for immunohistochemistry. The mean diameter of the prostatic intraepithelial neoplasia foci evaluated in our study was 1.8 mm, the individual values ranging from 0.5 to 2.5 mm. The extension of prostatic intraepithelial neoplasia in the five groups was comparable. In

Table 1 Group composition

<i>Group 1</i>
High grade prostatic intraepithelial neoplasia of the transition zone not associated with developing prostatic carcinoma (thus isolated). This lesion was present in 7 simple prostatectomy and in 3 cystoprostatectomy specimens from patients operated on because of benign prostatic hyperplasia and bladder cancer, respectively
<i>Group 2</i>
High grade prostatic intraepithelial neoplasia of the transition zone associated with developing prostatic carcinoma. The foci were identified in 8 simple prostatectomy and 2 cystoprostatectomy specimens from patients with benign prostatic hyperplasia and bladder cancer, respectively
<i>Group 3</i>
High grade prostatic intraepithelial neoplasia of the peripheral and central zones (in this study the central and peripheral zone are also referred to together as the outer prostate or "non-transition zone") not associated with developing prostatic carcinoma. This group was composed of 10 patients who had urothelial cell carcinoma of the urinary bladder and had undergone cystoprostatectomy
<i>Group 4</i>
High grade prostatic intraepithelial neoplasia of the non-transition zone associated with developing prostatic carcinoma. This group was composed of 10 patients with developing prostatic carcinoma diagnosed in a prostate biopsy. They underwent radical prostatectomy
<i>Group 5</i>
High grade prostatic intraepithelial neoplasia simultaneously present in the non-transition and transition zones and not associated with developing prostatic carcinoma. This group was composed of 6 patients who underwent cystoprostatectomy as a result of bladder cancer

those groups where cancer was present, this was always localised to the prostate (that is, pT2).

#### IMMUNOHISTOCHEMISTRY

Immunohistochemistry was performed on 5  $\mu$ m thick paraffin wax embedded tissue sections on poly-L-lysine coated glass slides. The sections were dried, dewaxed, and rehydrated. The sections were then pretreated with 0.3% hydrogen peroxide in methanol for 30 minutes. After an initial 20 minute incubation with 2% normal goat serum, the specimens were incubated overnight at 4°C with primary rabbit polyclonal anti-GST- $\pi$  antibody at a dilution of 1/500 (Delta Biologicals, Rome, Italy). After several washes in stock phosphate buffered saline (PBS), secondary antibody (biotinylated antirabbit IgG, at a dilution of 1/500; Vector Laboratories, Burlingame, California, USA) was applied to the sections and incubated for 60 minutes, followed by washing and incubation with an avidin-biotin-horseradish peroxidase complex (Vector Laboratories; reagents prepared according to the manufacturer's specifications) for 45 minutes. The sections were then washed in two cycles of stock PBS (five minutes each), and the peroxidase reaction developed using 3,3'-diaminobenzidine tetrahydrochlorate (DAB) diluted to 1% in PBS. Sections were incubated with this solution for five minutes and then thoroughly washed in water. The sections were differentiated with acid alcohol, washed in tap water, blue ammonia water, counterstained with a light haematoxylin and eosin, and dehydrated with three changes of 95% absolute ethanol and xylene (two minutes each). The sections were then coverslipped and mounted. Tissue sections from normal human liver containing hepatic bile ducts were used as positive controls, whereas the omission of primary antibodies on prostatic and liver sections served as negative controls.

All the sections were examined by light microscopy to assess qualitatively the presence or absence of immunostaining, and its distribution. Among the tissue that stained positive, a distinction was made between staining of the basal cell layer and the secretory acinar epithelium. Fisher's exact test was used for statistical analysis of the results.

#### Results

The anti-GST- $\pi$  antibody stained the cytoplasm of the cells lining the ducts and acini. In general, staining was stronger and more diffuse in the basal cell layer than in the secretory cell layer (figs 1 and 2). Focal and weak nuclear staining was present in the basal epithelial layer of 40% of cases. Short gaps in the immunostained basal cell layer were present. Some variability in the expression of GST- $\pi$  in the benign ducts and acini was seen within each zone and also between the prostate zones. Sections from five cases selected at random from the five groups were also immunostained for cytokeratin 34 $\beta$ E12. The extension of the basal cell layer staining with the two markers was comparable. In no instance was secretory layer

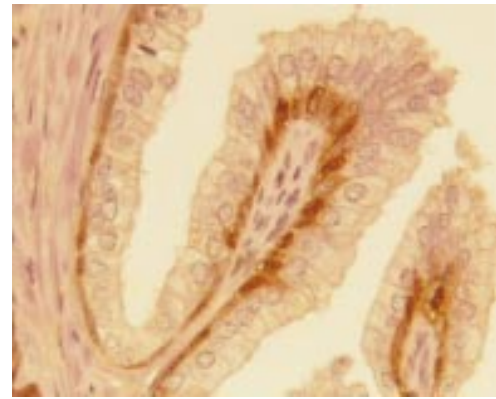


Figure 1 Normal prostate tissue. The antiglutathione S-transferase  $\pi$ -class (GST- $\pi$ ) antibody stained the cytoplasm and the nuclei of the basal cell layer.

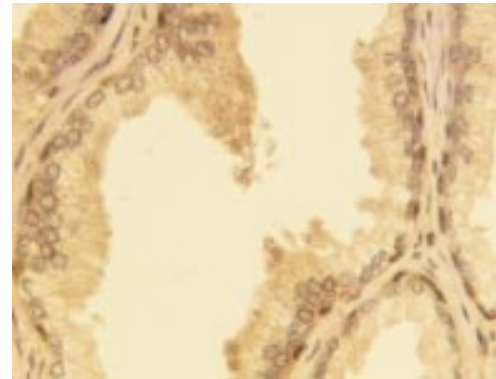


Figure 2 Normal prostate tissue. Glutathione S-transferase  $\pi$ -class (GST- $\pi$ ) staining is stronger in the basal cell layer than in the secretory cell layer.

staining for GST- $\pi$  present in the absence of basal layer staining. There was no appreciable difference in staining intensity between those secretory cells that faced or did not face an intact basal cell layer. The prostatic stroma was not immunoreactive, whereas the urothelium and squamous metaplastic epithelium were.

Prostate cancer was present in the samples included in group 2 (prostatic intraepithelial neoplasia associated with prostatic carcinoma in the transition zone) and group 4 (prostatic intraepithelial neoplasia associated with prostatic carcinoma in the non-transition zone). Prostatic carcinoma with Gleason pattern ranging from 2 to 3 was observed in the former group and with Gleason pattern ranging from 3 to 5 in the latter. Immunohistochemical staining with anti-GST- $\pi$  antibodies failed to detect the enzyme in all prostatic carcinoma areas apart from one. Weak staining of approximately 15% of cells was observed in a single focus with Gleason pattern 2. It was confirmed to be prostatic carcinoma by the absence of a basal cell layer with cytokeratin 34 $\beta$ E12 immunostaining. Cells undergoing either mitotic division or apoptosis did not express GST- $\pi$ .

Two discrete immunostaining patterns were seen in high grade prostatic intraepithelial neoplasia. GST- $\pi$  expression similar to that of the normal tissue; that is, stronger and more diffuse in the basal cell layer than in the luminal cell layer, was defined as pattern A (figs 3 and 4). The basal cell layer stained at the

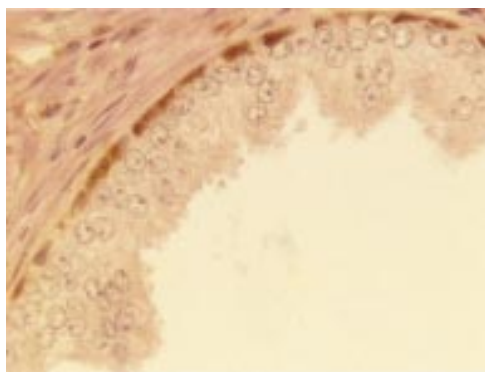


Figure 3 High grade prostatic intraepithelial neoplasia with diffuse glutathione S-transferase  $\pi$ -class (GST- $\pi$ ) expression in the basal cell layer (pattern A).

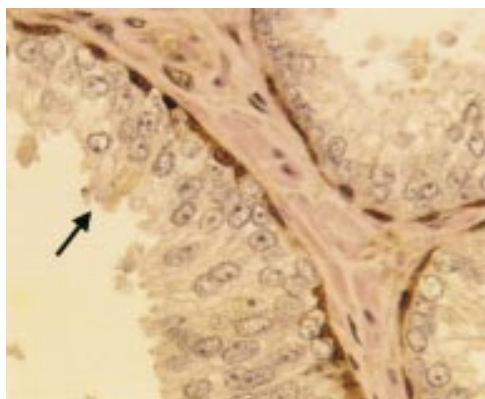


Figure 4 High grade prostatic intraepithelial neoplasia with diffuse glutathione S-transferase  $\pi$ -class (GST- $\pi$ ) expression in the basal cell layer. Scattered secretory cells (see arrow) show some positivity, mainly in the supranuclear region (pattern A).

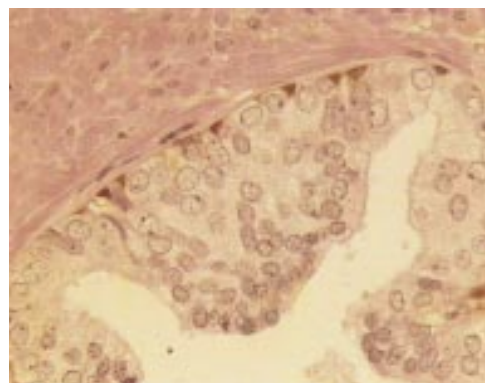


Figure 5 High grade prostatic intraepithelial neoplasia with complete absence of glutathione S-transferase  $\pi$ -class (GST- $\pi$ ) expression in the secretory cells and abundant expression in scattered basal cells (pattern B).

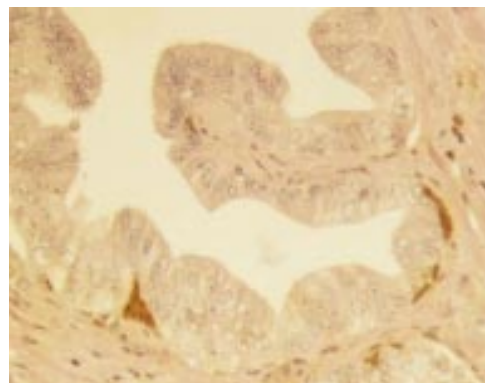


Figure 6 High grade prostatic intraepithelial neoplasia with complete absence of glutathione S-transferase  $\pi$ -class (GST- $\pi$ ) expression in the secretory cells and abundant expression in scattered basal cells (pattern B).

periphery was prominent at low magnification, partially and completely encircling acini and ducts containing prostatic intraepithelial neoplasia. The other pattern deviated from the normal and was characterised by complete absence of GST- $\pi$  expression in the secretory cells and abundant expression in scattered basal cells (pattern B) (figs 5 and 6). This pattern was identical to that observed by Cookson *et al.*<sup>27</sup> Coexistence of the two patterns in individual foci was not seen. A pattern intermediate between these two was seldom seen. Bostwick and colleagues<sup>34</sup> identified four architectural patterns of high grade prostatic intraepithelial neoplasia: tufting, micropapillary, cribriform, and flat. In our material, epithelial tufting was the most common architectural pattern, being seen in 97% of the prostatic intraepithelial neoplasia foci. There was no relation between the pattern of GST- $\pi$  expression and prostatic intraepithelial neoplasia architecture.

When the high grade prostatic intraepithelial neoplasia lesions were divided according to whether they were either isolated or associated with prostatic carcinoma, the pattern A of GST- $\pi$  expression was prevalent in the samples of high grade prostatic intraepithelial neoplasia that were isolated and not associated with prostatic carcinoma. In addition, when considering the zonal distribution, high grade prostatic intraepithelial neoplasia with pattern A was

prevalent in the transition zone, the differences being significant. This indicates that pattern B was seen mainly in cases of high grade prostatic intraepithelial neoplasia associated with prostatic carcinoma and present in the non-transition zone. In groups 2 and 4, high grade prostatic intraepithelial neoplasia was either adjacent to or remote from cancer; pattern B was prevalent in high grade prostatic intraepithelial neoplasia adjacent to prostatic carcinoma in the non-transition zone, although the

Table 2 Expression of  $\pi$ -class glutathione S-transferase (GST- $\pi$ ) in high grade prostatic intraepithelial neoplasia (PIN)

	GST- $\pi$ immunostaining of PIN		p Value
	Pattern A	Pattern B	
Group 1	9 (90%)	1 (10%)	NS
Group 2	7 (70%)	3 (30%)	
Group 3	3 (30%)	7 (70%)	NS
Group 4	3 (30%)	7 (70%)	
Group 5			NS
Trans. zone	4 (66%)	2 (33%)	
Non-trans.	2 (33%)	4 (66%)	

Group 1, high grade PIN of the transition zone isolated; group 2, high grade PIN of the transition zone associated with prostatic carcinoma (PCa); group 3, high grade PIN of the non-transition zone isolated; group 4, high grade PIN of the non-transition zone associated with PCa; group 5, high grade PIN, isolated and simultaneously present in the transition and non-transition zones.

Values are number of cases and frequency in parenthesis.

NS, not significant; trans., transition zone.

Additional statistics: group 1 v group 3,  $p = 0.022$ ; group 2 v group 4,  $p = 0.180$ .

Table 3 Expression of  $\pi$ -class glutathione S-transferase (GST- $\pi$ ) in high grade prostatic intraepithelial neoplasia (PIN) subdivided according to the proximity to developing prostatic carcinoma (PCa)

	GST- $\pi$ immunostaining of PIN		p Value
	Pattern A	Pattern B	
<i>Group 2</i>			
High grade PIN adjacent to PCa	3 (30%)	2 (20%)	NS
High grade PIN remote from PCa	4 (40%)	1 (10%)	
<i>Group 4</i>			
High grade PIN adjacent to PCa	1 (10%)	6 (60%)	NS
High grade PIN remote from PCa	2 (20%)	1 (10%)	

NS, not significant.

Table 4 Confusion matrix of the expression of  $\pi$ -class glutathione S-transferase (GST- $\pi$ ) in high grade prostatic intraepithelial neoplasia (PIN) in group 5

	Transition zone	
	Pattern A	Pattern B
<i>Non-transition zone</i>		
Pattern A	2 (33%)	0
Pattern B	2 (33%)	2 (33%)

Concordance in the patterns between the transition and non-transition zones was seen in four of six cases (66%) (not significant).

differences were not significant (tables 2 and 3). In particular, when pattern B was observed in high grade prostatic intraepithelial neoplasia lesions of the transition zone, the same pattern was also present in the non-transition zone of the same prostates (table 4). There was no correlation between the GST- $\pi$  pattern of staining in high grade prostatic intraepithelial neoplasia and the Gleason pattern. High grade prostatic intraepithelial neoplasia with early invasion—that is, with transition to prostatic carcinoma—was present in one sample from group 4. This lesion showed pattern B staining.

In some whole mount sections, prostatic intraepithelial neoplasia foci smaller than those evaluated in our study were present. In general, these additional foci showed GST- $\pi$  expression similar to that of the main foci whose evaluation was detailed above (data not shown).

## Discussion

The expression of GST- $\pi$  in normal prostate tissue specimens, including those from patients with benign prostatic hyperplasia, has been investigated in previous studies.<sup>14 27 33–36</sup> Their findings were confirmed in our investigation, where diffuse cytoplasmic immunostaining in the basal cell layer was seen, and only a minority of secretory cells were stained. Although most of the GST- $\pi$  was cytosolic, nuclear staining was reported by Moskaluk *et al*,<sup>31</sup> who found that approximately 50% of cases also exhibited focal nuclear staining, primarily in the basal epithelial layer. Our findings on nuclear staining were similar to those reported by Moskaluk *et al*.<sup>31</sup>

The benign ducts and acini evaluated in our study showed some variability in GST- $\pi$  expression and in the proportion of stained cells both within and between the prostate zones. However, the staining of basal and secretory cells in the transition and non-transition zones was qualitatively similar. This is in agreement with a previous study by our

group.<sup>36</sup> No substantial differences were seen between the samples from patients with benign prostatic hyperplasia and those derived from patients unaffected by this disease. Our findings are in agreement with the data derived from a biochemical study performed by Tew *et al*.<sup>35</sup>

De Marzo and colleagues<sup>37</sup> proposed that most proliferating cells in normal prostate and benign prostatic hyperplasia tissue reside in the basal cell compartment. Higher amounts of gene products that appear to have genomic protective features, such as GST- $\pi$ , are found in the basal cells. Other potentially protective molecules are preferentially expressed in basal cells versus secretory cells, including glyceraldehyde-3-phosphate dehydrogenase, which has been shown to be involved in DNA repair, and pp32, which inhibits neoplastic transformation *in vitro*.<sup>37</sup> Therefore, with these protective functions intact, the basal cells are immune from the acquisition of multiple genomic changes and, hence, the extreme rarity of prostatic basal cell carcinoma.

The results of our study and of previous investigations<sup>14 27 33–36</sup> have shown that only a minority of cells in the secretory compartment stain for GST- $\pi$ , and only weakly. It has been speculated that in normal prostate tissue the basal cells exert some protective influence on the secretory cell compartment. When basal cells are not present, such as in the gaps present in the basal cell layer, the luminal cells might take up this protective role.<sup>36</sup> It is possible that the early loss of GST- $\pi$  expression in human prostate cells might compromise their electrophilic defences, making them vulnerable to the accumulation of the genetic damage necessary to foster the neoplastic transformation.

Prostatic carcinoma is thought to initiate from an abnormal increase in replication of transiently proliferating cells within the secretory compartment that are poorly protected against DNA damage.<sup>37</sup> Although these cells have partial differentiation ability, they abnormally retain or acquire stem cell like features of unlimited self renewal. The immortal nature of the expanding clone, which is proliferating without adequate DNA protection, allows the accumulation of additional genetic damage and genetic instability, thus resulting in the development of prostate cancer. Previous investigations showed that immunohistochemical staining with anti-GST- $\pi$  antibodies failed to detect the enzyme in most untreated prostatic adenocarcinomas, despite the presence of abundant staining in normal prostatic epithelial cells and in cells making up benign proliferative prostatic lesions.<sup>26 27 31 33</sup> For example, Cookson and colleagues<sup>27</sup> reported GST- $\pi$  expression in only 4% of cases. The almost complete absence of GST- $\pi$  expression in prostatic carcinoma seen by others was also confirmed in our study. Of the 20 prostatic carcinomas tested, only one was focally positive for GST- $\pi$ . The lack of GST- $\pi$  expression among prostate carcinomas appears to be independent of tumour biology and again there appears to be little

prognostic information available because even incidental tumours lack staining in almost all cases.

The lack of GST- $\pi$  expression in prostatic carcinoma has been linked to the fact that the regulatory sequences near the gene GSTP1, which encodes the human  $\pi$ -class GST, often appear to be hypermethylated during prostatic carcinogenesis.<sup>28–30</sup> These studies identify changes in GST- $\pi$  expression as the most common genetic alteration in the process of prostate cancer development. Total androgen ablation does not restore the expression of this enzyme, indicating that the genetic defect detected in prostate cancer is not reversible under androgen manipulation. A different point of view was expressed by Cookson *et al.*,<sup>27</sup> who questioned the hypothesis of the role of GST- $\pi$  in the malignant transformation of prostatic acinar epithelium. The lack of GST- $\pi$  expression seen in prostate cancer might be related to the absence of the basal cell layer. If the basal cell is the precursor stem cell of the secretory acinar cell, it is possible that GST- $\pi$  is necessary to maintain the basal cell phenotype and is lost as it differentiates into an acinar cell. However, this view is not shared by other researchers who favour the role of GST- $\pi$  in prostate carcinogenesis through an intermediate step defined as high grade prostatic intraepithelial neoplasia.<sup>28–30</sup>

GST- $\pi$  expression in high grade prostatic intraepithelial neoplasia was investigated in previous studies. Cookson and colleagues<sup>27</sup> reported GST- $\pi$  expression in only one of 17 high grade prostatic intraepithelial neoplasia lesions. Similarly, Lee and colleagues<sup>30</sup> reported detecting heterogeneity in GST- $\pi$  expression in a small number of prostatic intraepithelial neoplasia lesions in which occasional cells displayed GST- $\pi$  expression. Subsequently, Lee's group reviewed the specimens and raised the possibility that the cells expressing GST- $\pi$  might have been basal cells or normal columnar epithelial cells interspersed in the foci of prostatic intraepithelial neoplasia. Moskaluk and colleagues<sup>31</sup> found absent GST- $\pi$  expression in 12 of 12 high grade prostatic intraepithelial neoplasia specimens. Similarly, GST- $\pi$  expression was completely absent from 60 independent high grade prostatic intraepithelial neoplasia foci analysed by Brooks *et al.*<sup>26</sup> In this last study, lack of GST- $\pi$  expression in high grade prostatic intraepithelial neoplasia was associated with CG island methylation changes near the GSTP1 gene in seven of 10 high grade prostatic intraepithelial neoplasia lesions. These authors speculated that prostatic intraepithelial neoplasia lesions that lack GSTP1 promoter methylation might never progress to carcinoma. In addition, they suggested that the detection of methylated GSTP1 promoter sequences might serve as a useful biomarker of high grade prostatic intraepithelial neoplasia lesions at risk for progression.<sup>26</sup>

We found two staining patterns in high grade prostatic intraepithelial neoplasia lesions. One was similar to the pattern of normal tissue, whereas the other differed from it consistently.

Our study on GST- $\pi$  expression in high grade prostatic intraepithelial neoplasia shows some discrepancy with the observations made by Brooks and colleagues<sup>26</sup> and Cookson *et al.*,<sup>27</sup> whereas it is partially in agreement with the information given by Moskaluk and colleagues<sup>31</sup> and Lee *et al.*<sup>29–30</sup> Such differences could be explained on the basis of the type of prostatic intraepithelial neoplasia studied. We selected high grade prostatic intraepithelial neoplasia samples (some of which were associated with cancer whereas others were not) belonging to different prostate zones. The aforementioned authors always selected foci of high grade prostatic intraepithelial neoplasia present in prostates from patients with prostatic carcinoma, and the zonal distribution of these lesions was never considered.<sup>26–27–29–31</sup>

Even though our study did not include molecular testing of GST- $\pi$  expression, the immunohistochemical results point towards the identification of two populations with the morphological appearance of high grade prostatic intraepithelial neoplasia. Those prostatic intraepithelial neoplasia lesions whose GST- $\pi$  expression is substantially different from that seen in normal tissue—namely, the cases of non-transition zone either adjacent to or remote from prostatic carcinoma—are closely associated with cancer. By contrast, enzyme expression in prostatic intraepithelial neoplasia lesions of the transition zone is very similar to that seen in normal tissue, and these lesions have a different association with cancer. This is in keeping with the results of a recent publication by Harvei *et al.*<sup>7</sup> These authors investigated prostatic intraepithelial neoplasia in the transition/central zone as a marker for subsequent development of prostatic carcinoma. They did not find any association between the presence of prostatic intraepithelial neoplasia in this zone and subsequent cancer development, thus questioning the precursor nature of prostatic intraepithelial neoplasia at this location. A recent publication by Weinstein gives further support for the existence of two distinct populations of high grade prostatic intraepithelial neoplasia.<sup>38</sup> According to this author, the categorisation of prostatic intraepithelial neoplasia based on the degree of proliferation measured by digital image analysis has biological relevance.

In conclusion, the differential expression of GST- $\pi$  in the transition and non-transition zones indicates the existence of two populations with the morphological appearance of high grade prostatic intraepithelial neoplasia but with different relations to carcinoma. Quantitative analytical studies using image analysis systems are in progress and should provide us with additional information on the activity of GST- $\pi$ .

This research has been supported by a grant from the University of Ancona and, in part, by a grant from the National Cancer Institute, R 35 CA 53877 (PHB). The content of this paper is solely the responsibility of the authors and does not necessarily represent the official views of the University of Ancona and the National Cancer Institute.

- 1 Bostwick DG. High grade prostatic intraepithelial neoplasia. The most likely precursor of prostate cancer. *Cancer* 1995;75:1823-36.
- 2 Bonkhoff H. Role of the basal cells in premalignant changes of the human prostate: a stem cell concept for the development of prostate cancer. *Eur Urol* 1996;30:201-5.
- 3 Montironi R, Schulman CC. Precursors of prostatic cancer: progression, regression and chemoprevention. *Eur Urol* 1996;30:133-7.
- 4 Brawley OW, Thompson IM. Chemoprevention of prostate cancer and the prostate cancer prevention trial. In: Schroeder FH, ed. *Recent advances in prostate cancer and BPH*. New York: The Parthenon Publishing Group, 1997: 51-9.
- 5 Weinstein MH, Epstein JI. Significance of high-grade prostatic intraepithelial neoplasia on needle biopsy. *Hum Pathol* 1993;24:624-9.
- 6 Pacelli A, Bostwick DG. Clinical significance of high-grade prostatic intraepithelial neoplasia in transurethral resection specimens. *Urology* 1997;50:355-9.
- 7 Harvei S, SkjØrten FJ, Røsbak, et al. Is prostatic intraepithelial neoplasia in the transition/central zone a true precursor of cancer? A long-term retrospective study in Norway. *Br J Cancer* 1998;78:46-9.
- 8 Mannervik B, Awasthi YC, Board PG, et al. Nomenclature for human glutathione transferases. *Biochem J* 1992;282: 305-8.
- 9 Ripple M, Mulcahy RT, Wilding G. Characteristics of the glutathione/glutathione-S-transferase detoxification system in melphalan resistant human prostate cancer cells. *J Urol* 1993;150:209-14.
- 10 Ryberg D, Skaug V, Hewer A, et al. Genotypes of glutathione transferase M1 and P1 and their significance for lung DNA adducts levels and cancer risk. *Carcinogenesis* 1997;18: 1285-9.
- 11 Campbell JAH, Corrigan AV, Guy A, et al. Immunohistochemical localization of alpha, mu, and pi class glutathione S-transferases in human tissues. *Cancer* 1991;67:1608-13.
- 12 Baylin SB, Makos M, Wu JJ, et al. Abnormal patterns of DNA methylation in human neoplasia: potential consequences for tumor progression. *Cancer Cells (Cold Spring Harbor)* 1991;3:383-90.
- 13 Cairns J, Wright C, Cattar AR, et al. Immunohistochemical demonstration of glutathione S-transferases in primary human breast carcinomas. *J Pathol* 1992;166:19-25.
- 14 Canada AT, Roberson KM, Vessella RL, et al. Glutathione and glutathione S-transferase in benign and malignant prostate cell lines and prostate tissue. *Biochem Pharmacol* 1996;51:87-90.
- 15 Di Ilio C, Aceto A, Bucciarelli T, et al. Glutathione transferase isoenzymes from human prostate. *Biochem J* 1990;271:481-5.
- 16 Green JA, Robertson LJ, Clark AH. Glutathione S-transferase expression in benign and malignant ovarian tumours. *Br J Cancer* 1993;68:235-9.
- 17 Harries TK, Stubbs MJ, Forman D, et al. Identification of genetic polymorphisms at the glutathione S-transferase  $\pi$  locus and association with susceptibility to bladder, testicular and prostate cancer. *Carcinogenesis* 1997;18:641-4.
- 18 Hirata S, Odajima T, Kohama GI, et al. Significance of glutathione S-transferase- $\pi$  as a tumor marker in patients with oral cancer. *Cancer* 1992;70:2381-7.
- 19 Moscow JA, Fairchild CR, Madden MJ, et al. Expression of anionic glutathione-S-transferase and p-glycoprotein genes in human tissue and tumors. *Cancer Res* 1989;49:1422-8.
- 20 Niitsu Y, Takahashi Y, Saito T, et al. Serum glutathione-S-transferase- $\pi$  as a tumor marker for gastrointestinal malignancies. *Cancer* 1989;63:317-23.
- 21 Randall BJ, Angus B, Akiba R, et al. Glutathione S-transferase (placental) as a marker of transformation in the human cervix uteri: an immunohistochemical study. *Br J Cancer* 1990;62:614-18.
- 22 Shiratori Y, Soma Y, Maruyama H, et al. Immunohistochemical detection of the placental form of glutathione S-transferase in dysplastic and neoplastic human uterine cervix lesions. *Cancer Res* 1987;47:6806-9.
- 23 Terrier P, Townsend AJ, Coindre JM, et al. An immunohistochemical study of pi class glutathione S-transferase expression in normal human tissue. *Am J Pathol* 1990;137: 845-53.
- 24 Thomas DJ, Birch PJ, Vickers J, et al. Glutathione-S-transferase  $\pi$  expression in transitional cell carcinoma of the bladder. *Br J Urol* 1993;72:740-3.
- 25 Toffoli G, Viel A, Tumiotto L, et al. Expression of glutathione-S-transferase- $\pi$  in human tumours. *Eur J Cancer* 1992;28a:1441-6.
- 26 Brooks JD, Weinstein M, Lin X, et al. CH island methylation changes near the GSTP1 gene in prostatic intraepithelial neoplasia. *Cancer Epidemiol Biomarkers Prev* 1998;7:531-6.
- 27 Cookson MS, Reuter VE, Linkov I, et al. Glutathione S-transferase pi (GST- $\pi$ ) class expression by immunohistochemistry in benign and malignant prostate tissue. *J Urol* 1997;157:673-6.
- 28 Jarrard DF, Bova GS, Isaacs WB. DNA methylation, molecular genetic, and linkage studies in prostate cancer. *Prostate* 1996;6(suppl):36-44.
- 29 Lee WH, Isaacs WB, Bova GS, et al. CG island methylation changes near the GSTP1 gene in prostatic carcinoma cells detected using the polymerase chain reaction: a new prostatic biomarker. *Cancer Epidemiol Biomarkers Prev* 1997;6: 443-50.
- 30 Lee WH, Morton RA, Epstein JI, et al. Cytidine methylation of regulatory sequences near the  $\pi$ -class glutathione S-transferase gene accompanies human prostatic carcinogenesis. *Proc Natl Acad Sci U S A* 1994;91:11733-7.
- 31 Moskaluk CA, Duray PH, Cowan KH, et al. Immunohistochemical expression of  $\pi$ -class glutathione S-transferase is down-regulated in adenocarcinoma of the prostate. *Cancer* 1997;79:1595-9.
- 32 Nelson JB, Lee WH, Nguyen SH, et al. Methylation of the 5' CpG island of the endothelin B receptor gene is common in human prostate cancer. *Cancer Res* 1997;57:35-7.
- 33 Yang ES, David-Beabes GL, Veeraswamy R, et al. Expression of DNA methyl-transferase in normal human prostate, prostate cancer and prostate cancer lines. *Proceedings of the American Association for Cancer Research* 1997;38:182.5]
- 34 Bostwick DG, Amin MB, Dundore P, et al. Architectural patterns in high-grade prostatic intraepithelial neoplasia. *Hum Pathol* 1993;24:298-310.
- 35 Tew KD, Clapper ML, Greenberg RE, et al. Glutathione S-transferase in human prostate. *Biochim Biophys Acta* 1987;926:8-15.
- 36 Montironi R, Mazzucchelli R, Pomante R, et al. Immunohistochemical expression of  $\pi$ -class glutathione S-transferase in the basal cell layer of benign prostate tissue following chronic treatment with finasteride. *J Clin Pathol* 1999;52:350-4.
- 37 De Marzo AM, Nelson W, Meeker AK, et al. Stem cell features of benign and malignant prostate epithelial cells. *J Urol* 1998;160:2381-92.
- 38 Weinstein MH. Digital image analysis of proliferative index: two distinct populations of high-grade prostatic intraepithelial neoplasia in close proximity to adenocarcinoma of the prostate. *Hum Pathol* 1998;29:620-6.



## Expression of $\pi$ -class glutathione S-transferase: two populations of high grade prostatic intraepithelial neoplasia with different relations to carcinoma

R Montironi, R Mazzucchelli, D Stramazzotti, et al.

*Mol Path* 2000 53: 122-128

doi: 10.1136/mp.53.3.122

---

Updated information and services can be found at:

<http://mp.bmj.com/content/53/3/122.full.html>

---

*These include:*

### References

This article cites 35 articles, 9 of which can be accessed free at:

<http://mp.bmj.com/content/53/3/122.full.html#ref-list-1>

Article cited in:

<http://mp.bmj.com/content/53/3/122.full.html#related-urls>

### Email alerting service

Receive free email alerts when new articles cite this article. Sign up in the box at the top right corner of the online article.

---

### Notes

---

To request permissions go to:

<http://group.bmj.com/group/rights-licensing/permissions>

To order reprints go to:

<http://journals.bmj.com/cgi/reprintform>

To subscribe to BMJ go to:

<http://group.bmj.com/subscribe/>