

ORIGINAL ARTICLE

Laminin 5 γ 2 chain expression: a marker of early invasiveness in colorectal adenomas

C Lenander, U J Roblick, J K Habermann, Å Öst, K Tryggvason, G Auer

J Clin Pathol: Mol Pathol 2003;56:342–346

Aim: Polyps of the colon and rectum are considered to be premalignant lesions in the development of colorectal cancer. However, knowledge of how normal epithelial cells gain invasive properties is limited. Laminin 5 γ 2 chain expression was investigated to determine the role of laminin 5 as a marker of potential invasiveness in colorectal polyps.

Material/methods: Sixty seven polyps of different types (15 hyperplastic polyps, 12 serrated adenomas, 16 tubular adenomas, and 24 adenomas with a villous component) were assessed for γ 2 chain expression of laminin 5 by immunohistochemistry on archival, paraffin wax embedded sections.

Results: Ten polyps stained positive and the number of polyps expressing the laminin 5 γ 2 chain increased significantly as the phenotype of the adenomas became more atypical: none of the 15 hyperplastic polyps, two of the 16 tubular adenomas (12.5%), and six of the 24 adenomas with a villous component (25%) were positive. Two of 12 (17%) serrated adenomas, regarded as a distinct form of colorectal neoplasia, showed γ 2 chain expression. Furthermore, laminin 5 γ 2 chain expression correlated with lesion size. Polyps smaller than 10 mm expressed the γ 2 chain less frequently than did those equal to or larger than 10 mm.

Conclusion: Laminin 5 γ 2 chain expression was found to increase progressively towards a more atypical phenotype of adenoma. The results suggest that, in the future, laminin 5 γ 2 chain expression may be used as an indicator of incipient malignant transformation of a benign colorectal adenoma.

See end of article for authors' affiliations

Correspondence to:
Dr C Lenander MD PhD,
Ersta Hospital, Box 4622,
S-11691, Stockholm,
Sweden; claes.lenander@
ersta.se

Accepted for publication
5 July 2003

It is now well established that most colorectal carcinomas (CRCs) arise from benign adenomas, and that individuals having an adenoma are at higher risk of developing CRC.^{1,2} These epidemiological observations are based on the fact that the prevalence of adenomas within a population parallels geographically the prevalence of colon cancer.³ Furthermore, both conditions increase with age and adenomas have been found to precede carcinomas by five to 10 years. Clinical studies have also shown that removal of polyps prevents the development of colorectal cancer.^{4,5}

Although adenomas are considered to be benign, 3–12% of the polyps are known to present as invasive carcinomas at the time of diagnosis.^{6,7} Even if it is not clear how benign adenomas develop into malignant lesions, genomic aberrations have been suggested to play an important role in malignant transformation because most of the CRCs (80–90%) show chromosomal instability. A proposal concerning the origin of this instability was presented in a classic study by Fearon and Vogelstein. These authors suggested that progressive histological abnormalities in adenomas coincide with the sequential accumulation of genetic defects within the cells.⁸

Traditionally, colorectal polyps are divided into two subtypes: hyperplastic polyps and adenomas (tubular, tubulovillous, and villous). Although hyperplastic polyps are regarded as non-premalignant lesions, they have recently been described as potential risk markers.^{9,10} The rate of invasive carcinomas within colorectal adenomas has been estimated to be 4–5% for tubular adenomas and 30% for adenomas with a villous component.¹¹

In 1990, Longacre and Fenoglio-Preiser described polyps in which the epithelium showed a mixed feature of hyperplastic and adenomatous structures expressing cytologically neoplastic characteristics, which they termed "serrated adenomas" (SAs).¹² They found intramucosal carcinomas in 10% of

their SAs, whereas more recent investigators have reported malignancy in up to 20% of all SA cases.^{12,13}

"It has been claimed that laminin 5 promotes cell migration and/or invasion after the γ 2 chain has been cleaved by metalloproteinases"

In the process of invasion, epithelial cancer cells need to penetrate the basement membrane and subsequently migrate into the extracellular matrix (ECM). Here, proteases, such as metalloproteinases (MMPs) and serine proteases, degrade or process the ECM for further dissemination of the cancer cells. Laminins are a group of matrix proteins localised at the basement membrane where they are involved in cell adhesion. The laminin (ln) family consists of cross shaped heterotrimers composed of α , β , and γ subunits. At present, 11 isoforms of the molecule have been described, reflecting diverse tissue specificities and biological functions, such as cell adhesion, migration, proliferation, growth, and differentiation.^{14–16} One isoform, ln-5, is composed of α 3, β 3, and γ 2 chains, each encoded by different genes, namely: LAMA3 (18q 11.2), LAMB3 (1q 32), and LAMC2 (1q 25–31).^{17–19} Interacting with integrins, ln-5 anchors the epithelial cells to the basement membrane.^{20–26} Furthermore, it has been claimed that ln-5 promotes cell migration and/or invasion after the γ 2 chain has been cleaved by MMPs (MMP-2 and membrane type 1 MMP) secreted by cancer cells or neighbouring stroma cells.^{27,28}

Abbreviations: CRC, colorectal carcinoma; ECM, extracellular matrix; ln, laminin; MMP, metalloproteinase; SA, serrated adenoma; TBS, Tris buffered saline

Accumulating data suggest that ln-5 γ 2 chain expression is increased during carcinogenesis.^{25–35} This is in accord with our studies, which show that ln-5 γ 2 chain expression is upregulated during the progression of human colon cancer.³⁶ In another study, we found that ln-5 may help to identify patients with ulcerative colitis who have an increased risk for CRC.³⁷

The aim of our present study was to investigate the expression of the ln-5 γ 2 chain in subtypes of colorectal polyps known to constitute different risk lesions.

MATERIALS AND METHODS

Tissue samples

Between 1993 and 1999, a total of 67 polyps (size range, 1–110 mm; mean, 17.1) were collected from 49 patients. Forty nine polyps were removed endoscopically, whereas the remaining 18 were obtained from surgical specimens. All specimens were selected according to the original histopathological report. To confirm the original diagnosis and sample representativity, all haematoxylin and eosin stained slides were reviewed by an independent pathologist (ÅÖ). Classification for histological type and grade of atypia was carried out in accordance with the World Health Organisation classification.³⁸ After reclassification, the material consisted of 15 hyperplastic polyps, 16 tubular adenomas, 24 adenomas with a villous component, and 12 SAs. Nine patients, in whom the polyps originated from a resection specimen, suffered from a synchronous carcinoma in a different part of the colon. The SAs were classified as a polyp expressing dysplastic adenomatous epithelium in the deeper part of the crypts, in combination with the saw tooth (serrated) configuration of a hyperplastic polyp on the surface.^{12–39}

Ten polyps were classified as right sided (caecum to the mid-transverse colon), 26 as left sided (from the mid-transverse colon to the rectum), and 27 as rectal (up to 15 cm from the anal verge). For four polyps, we were unable to give an exact location of the origin from the colonoscopic report. Our study was approved by the Karolinska Institute local ethics committee and all participating subjects gave fully informed consent.

Immunohistochemistry

The polyclonal antibody was raised in rabbits against a fusion protein containing the C-terminus of the ln γ 2 chain (amino acid residues 1017–1178) and glutathione-S-transferase. Preparation and characterisation were done according to methods described previously.⁴⁰

Representative blocks of formalin fixed, paraffin wax embedded sections from colon polyps were subjected to a standard horseradish peroxidase avidin–biotin complex procedure (Elite Standard kit; catalogue number PK-6100; Vector Laboratories Inc, Burlingame, California, USA). In brief, the sections (5 μ m thick) were dewaxed with xylene, rehydrated, and microwaved for 10 minutes at 500 W in 10mM sodium citrate buffer (pH 6). After a brief rinse in Tris

buffered saline (TBS) (pH 7.6), the sections were treated with 0.5% hydrogen peroxidase in distilled water for 30 minutes to block endogenous peroxidase activity. To reduce non-specific staining, the sections were exposed to 1% bovine serum albumin in TBS for 20 minutes. The sections were then incubated with the rabbit polyclonal antibody to the γ 2 chain of ln-5 (1/500 dilution) at 4°C overnight. This was followed by incubation with a biotinylated antirabbit IgG (1/200 dilution) for 30 minutes. After rinsing in TBS, the biotinylated secondary antibody and the horseradish peroxidase conjugated antibiotin antibody (Vector Elite standard kit; catalogue number PK-6100) were applied to the sections according to the manufacturer's instructions. The peroxidase activity was visualised with diaminobenzidine tetrahydrochloride (0.6 mg/ml with 0.03% H₂O₂) for six minutes. Counterstaining was performed using Mayer's haematoxylin and, finally, the slides were dehydrated and mounted. Parallel incubations of adjacent sections in which the primary antibody was omitted served as negative controls.

Cytoplasmic staining of the ln-5 γ 2 chain was defined as the percentage of stained cells, with \leq 5% being regarded as negative and $>$ 5% as positive staining. The slides were evaluated independently by two investigators (CL and GA), and all cases with discrepant scores were reviewed until a conclusive judgement was reached. All evaluations were performed in a blinded manner without knowledge of the patient's clinical and pathological background.

Statistical analysis

The pattern of associations between ln-5 γ 2 chain expression and clinicopathological parameters was determined by means of the χ^2 exact test for trend (two sided).

RESULTS

We investigated 67 polyps regarding their expression of the ln-5 γ 2 chain. Tables 1–3 and fig 1 summarise the results. Immunoreactivity for the ln-5 γ 2 chain occurred in all cases only in the cytoplasm and epithelial cells of normal mucosa, and hyperplastic polyps were consistently negative (fig 2).

ln-5 γ 2 chain staining was positive in 10 of the total number of 67 polyps. No hyperplastic polyps stained positively, whereas 10 of the 52 adenomas expressed the γ 2 chain. Significantly increasing numbers of polyps showed expression of the ln-5 γ 2 chain from hyperplastic polyps (none of 15) to tubular adenomas (two of 16; 12.5%) and adenomas with a villous component (six of 24; 25%) ($p = 0.037$). ln-5 γ 2 chain expression was also related to increasing polyp size ($p < 0.022$). Polyps smaller than 10 mm (32 polyps) were less frequently γ 2 chain immunopositive than were polyps equal to or larger than 10 mm (31 polyps) ($p < 0.006$) (fig 1; table 3). We were not able to define the size of four polyps (one hyperplastic polyp, one tubular adenoma, and two villous adenomas) because they were resected using a piecemeal technique and no statements were given in the patient reports. Two of the 12 serrated

Table 1 Immunoreactivity for laminin 5 γ 2 in 67 colorectal polyps

Colorectal polyps	Number	Mean size (range) (mm)	Laminin 5		
			Negative	Positive	p Value
Hyperplastic polyps	15	6.3 (4–10)	15 (100)	0	0.037
Tubular adenomas	16	8.2 (2–20)	14 (87.5)	2 (12.5)	
Villous component	24	32.4 (8–110)	18 (75)	6 (25)	
Serrated adenomas	12	8.7 (1–30)	10 (83.3)	2 (16.7)	
Total	67	17.1 (1–110)	57 (85.1)	10 (14.9)	

Data for the laminin 5 positive and negative groups are given as numbers (%); for grading of laminin 5 γ 2 expression, see Material and Methods.

Table 2 Laminin 5 γ 2 expression in colorectal polyps and colon cancer

	Number	Laminin 5 (%)		p Value
		Negative	Positive	
Colorectal polyps	67	57 (85)	10 (15)	<0.001
Colon adenocarcinoma*	93	28 (30)	65 (70)	

Data for the laminin 5 positive and negative groups are given as numbers (%); for grading of laminin 5 γ 2 expression, see Material and Methods.
*Data from Lenander *et al.*³⁶

adenomas (17%) stained positively for the Ln-5 γ 2 chain. We found no significant differences in positive staining according to the patients' sex, tumour grade, or localisation of the polyps.

DISCUSSION

Several investigators have shown that the Ln-5 γ 2 chain is expressed in epithelial cells at the invasive front of malignant tumours.²⁹⁻³⁵ Furthermore, it has been stated that Ln-5 γ 2 chain expression is upregulated during human colon cancer progression and that expression can be related to the aggressive nature of a neoplasm.³⁶ To investigate the early steps of progression towards CRC, we analysed the Ln-5 γ 2 chain expression patterns in 67 polyps of different types. Based on the histological findings, we divided them into four groups to differentiate benign polyps (hyperplastic) from polyps with a malignant potential (tubular adenomas, adenomas comprising a villous component, and SAs).

Overall, 10 of the 67 (15%) polyps stained positive for the Ln-5 γ 2 chain and, considering only polyps with a malignant potential, in total, 10 of 52 (19%) expressed the Ln-5 γ 2 chain. In an earlier study, we showed that 96% of colon adenocarcinomas were positive for the γ 2 chain of Ln-5.³⁶ To date, only a few studies have investigated the possibility of using Ln-5 γ 2 chain expression as a preinvasive marker. However, our results are in concordance with the results of Skyldberg *et al*, who found γ 2 chain positivity in 22% of precancerous stages and in 100% of the investigated invasive cervical carcinomas.³² Habermann *et al* investigated the Ln-5 γ 2 chain as an early marker for risk assessment in patients

suffering from ulcerative colitis, a disease known to carry an increased risk of developing cancer. They found that the γ 2 chain was expressed in 20% of biopsies from a group of patients who later developed colorectal carcinoma.³⁷ However, the expression of the Ln-5 γ 2 chain in 19% of the adenomatous polyps reported here is in contrast to the findings of Sordat *et al*,²⁵ who found no cytoplasmic expression of the γ 2 chain in the 15 colorectal adenomas investigated.

In our study, Ln-5 γ 2 chain immunostaining was seen only in the cytoplasm of adenomatous epithelial cells located at the basal membrane, whereas epithelial cells of normal mucosa, in addition to all hyperplastic polyps, were negative. Ln-5 γ 2 chain expression in adenomas differs from the pattern seen in CRC. Here, the positive cells are located either near to the basal membrane, representing budding cells, or as scattered tumour cells in the stroma.^{29 30 36}

The subepithelial basal membrane plays an important role as a barrier at the epithelial-stromal junction and is lost in most invasive carcinomas, whereas its continuity is preserved in benign lesions. Neoplastic invasion requires degradation of the basal membrane and removal of ECM tissue boundaries, where MMPs and serine proteinases play a key role. Ln-5 is an extracellular matrix protein essential for static cell adhesion and, in addition, it promotes cell migration and/or invasion after being cleaved by MMPs. Interestingly, Koshikawa and colleagues²⁸ have suggested that membrane type 1 MMP, a cell surface anchored protein, which can both directly cleave the γ 2 chain and activate MMP-2, may play a role in the early phases of tissue invasion—for example, when a carcinoma in situ may still be dependent on external factors to initiate local invasion. According to this scenario, Ln-5 and in particular the γ 2 chain could be an efficient substrate for migrating cells.²⁹ It has also been suggested that the γ 2 chain of Ln-5 is involved in the metastatic process of several similar entities because it is expressed in the cytoplasm of cancer cells located at the invasion front.^{29 30 32 36 41} Furthermore, Giannelli and Antonaci emphasised that it is unusual for an extracellular molecule to have an intracellular distribution pattern.⁴²

The importance of γ 2 chain staining in the cytoplasm of colorectal polyps is not known. However, we have shown that the γ 2 chain of Ln-5 is widely expressed in preinvasive tissue

Table 3 Correlations between clinicopathological parameters and laminin 5 γ 2 chain expression in 67 colorectal polyps

	Number	Laminin 5 expression		Ln 5	p Value
		Negative	Positive	Positive (%)	
Sex					
Female	28	24 (86)	4 (14)	14.3	NS
Male	39	33 (85)	6 (15)	15.4	
Differentiation					
LGD	36	31 (86)	5 (14)	13.9	NS
HGD	16	11 (69)	5 (31)	31.3	
Size (mm)*					
≤ 5	18	17 (94)	1 (6)	5.6	0.022
6-9	14	14 (100)	0	0	
10-19	16	11 (69)	5 (31)	31.3	
≥ 20	15	11 (73)	4 (27)	26.7	
< 10	32	31 (97)	1 (3)	3.1	
≥ 10	31	22 (71)	9 (29)	29	0.006
Localisation*					
Right colon	10	9 (90)	1 (10)	10	NS
Left colon	26	24 (92)	2 (8)	7.7	
Rectum	27	21 (78)	6 (22)	22.2	

Data for the laminin 5 positive and negative groups are given as numbers (%); for grading of laminin 5 γ 2 expression, see Material and Methods.

*In four polyps, the size and localisation was not defined.

HGD, high grade dysplasia; LGD, low grade dysplasia; NS, not significant.

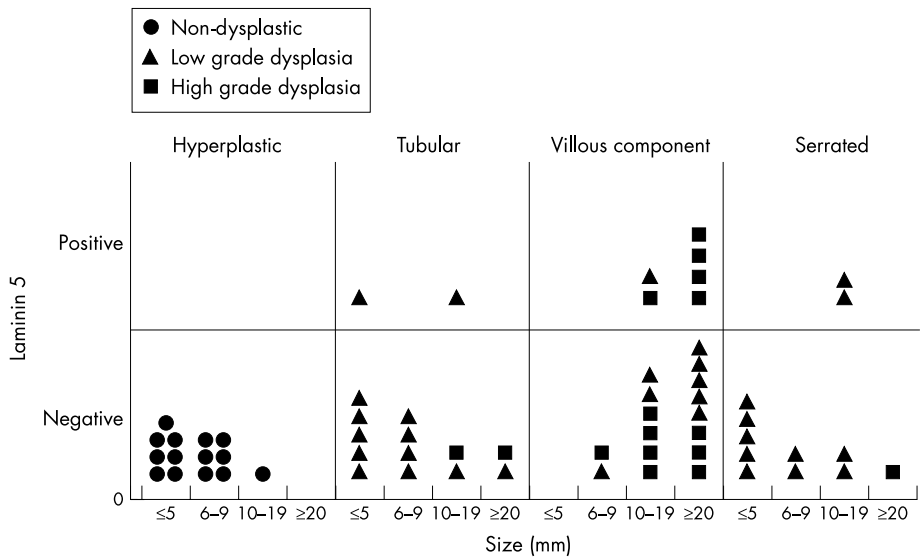


Figure 1 Laminin 5 $\gamma 2$ chain expression in relation to polyp type, size, and histological grade.

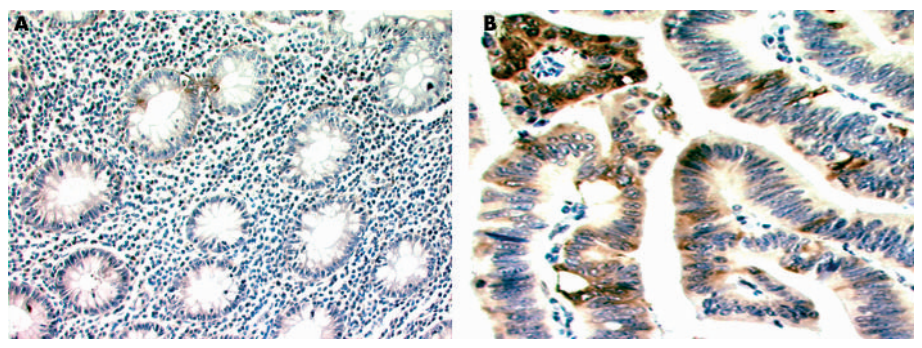


Figure 2 (A) Tubular adenoma showing negative staining. (B) Tubulovillous adenoma showing positive laminin 5 $\gamma 2$ chain staining (avidin-biotin complex technique).

such as in colon adenomas of various types, whereas no expression is seen in non-dysplastic lesions (hyperplastic polyps) or in normal epithelial cells lining the entire colon and rectum. It seems that structural changes in Ln-5 are relatively early events during the development of invasiveness.

Traditionally, hyperplastic polyps have been regarded as being non-neoplastic and lacking malignant potential. Despite new data indicating that a subset of hyperplastic polyps (right sided and/or large) might form a subtype with increased malignant potential,^{9 43 44} the fact remains that very small hyperplastic polyps, commonly encountered in the distal colon and in the rectum, lack malignant potential. In our study, this hypothesis regarding hyperplastic polyps as non-premalignant lesions was supported by the finding that none of these polyps was immunohistochemically positive for the Ln-5 $\gamma 2$ chain. However, most of these hyperplastic polyps were small (14 of 15 were < 10 mm) and 13 of 15 were located on the left side of the colon or in the rectum.

“We have shown that the $\gamma 2$ chain of laminin 5 is widely expressed in preinvasive tissue such as in colon adenomas of various types, whereas no expression is seen in non-dysplastic lesions (hyperplastic polyps) or in normal epithelial cells lining the entire colon and rectum”

It has been stated that SAs might be precursors of colorectal carcinoma with a tendency to malignant transformation similar to that of tubular adenomas. Therefore, we included 12 SAs, comprising different types of mixed

adenomatous tissue, in our study. Interestingly, a higher proportion of these lesions were positive for Ln-5 $\gamma 2$ expression (two of 12; 17%) compared with tubular adenomas (two of 16; 12.5%), although polyps including a villous component showed even higher expression (six of 24; 25%). This indicates that the risk for malignant progression of SAs is lower than for an adenomatous polyp including a villous component, but higher than for a tubular adenoma. This is in agreement with the literature, where the risk of developing into an invasive carcinoma has been estimated to be 4–5% for tubular adenomas, 10–20% for SAs, and 30% for adenomas including a villous component.^{1 7 12 13}

The overall incidence of carcinomas arising in adenomatous polyps according to size is approximately 5% for polyps less than 10 mm, 10% for polyps between 10 and 20 mm, and 45% for polyps larger than 20 mm.¹ Our data demonstrate a difference in the expression of the $\gamma 2$ chain according to size, where one of 32 (3%) polyps smaller than 10 mm showed positive staining compared with nine of 31 (29%) polyps larger than 10 mm ($p = 0.006$). In contrast to earlier observations in CRC,³⁶ there was no relation between Ln-5 $\gamma 2$ chain expression and the histopathological grade of differentiation.

As far as we know, this is the first report investigating the Ln-5 $\gamma 2$ chain staining pattern in colorectal polyps of various types. Based on our results, we suggest that Ln-5 $\gamma 2$ chain expression might be an early event during neoplastic progression towards colorectal cancer. This could be of paramount importance for therapeutic strategies and for designing surveillance programmes.

Take home messages

- Laminin 5 γ 2 chain expression was found to increase progressively towards a more atypical phenotype of adenoma
- Laminin 5 γ 2 chain expression also correlated with lesion size: γ 2 chain expression was higher in polyps \geq 10 mm than in those smaller than 10 mm
- Thus, laminin 5 γ 2 chain expression might be an early event during neoplastic progression towards colorectal cancer
- Laminin 5 γ 2 chain expression might be a useful indicator of incipient malignant transformation of a benign colorectal adenoma and could have an important part to play in therapeutic strategies and surveillance programmes

ACKNOWLEDGEMENTS

This work was financially supported by the Swedish Cancer Society (Cancerfonden), the Cancer Society in Stockholm (Cancerföreningen), the Stockholm County Council Public Health and Medical Services Committee R&D Department, and the Memorial Foundation of Sigurd and Elsa Golje (Stiftelsen Sigurd och Elsa Goljes minne). We are grateful to U Aspenblad and I Maurin for their excellent technical help and to B Nilsson for his statistical assistance.

Authors' affiliations

C Lenander, Centre of Gastrointestinal Disease, Department of Surgery, Ersta Hospital, S-11691, Stockholm, Sweden

G Auer, Division of Cellular and Molecular Tumour Pathology, Department of Oncology and Pathology, Karolinska Institutet, S-17176, Stockholm, Sweden

U J Roblick, **J K Habermann**, University of Schleswig-Holstein, Ratzeburger Allee 160, D-23438, Lübeck, Germany

Å Öst, Department of Pathology and Cytology, Medilab, PO Box 1550, S-18315, Täby, Sweden

K Tryggvason, Division of Matrix Biology, Department of Medical Biochemistry and Biophysics, Karolinska Institute, S-17177, Stockholm, Sweden

REFERENCES

- Muto T, Bussey HJ, Morson BC. The evolution of cancer of the colon and rectum. *Cancer* 1975;**36**:2251-70.
- Toribara NW, Sleisenger MH. Screening for colorectal cancer. *N Engl J Med* 1995;**332**:861-7.
- Correa P. Epidemiology of polyps and cancer. In: Morson B, ed. *The pathogenesis of colorectal cancer*. Philadelphia: WB Saunders Company, 1978:126-52.
- Gilbertsen VA, Nelms JM. The prevention of invasive cancer of the rectum. *Cancer* 1978;**41**:1137-9.
- Winawer SJ, Zauber AG, Ho MN, et al. Prevention of colorectal cancer by colonoscopic polypectomy. The national polyp study workgroup. *N Engl J Med* 1993;**329**:1977-81.
- Coverlizza S, Risio M, Ferrari A, et al. Colorectal adenomas containing invasive carcinoma. Pathologic assessment of lymph node metastatic potential. *Cancer* 1989;**64**:1937-47.
- Nusko G, Mansmann U, Altendorf-Hofmann A, et al. Risk of invasive carcinoma in colorectal adenomas assessed by size and site. *Int J Colorectal Dis* 1997;**12**:267-71.
- Fearon ER, Vogelstein B. A genetic model for colorectal tumorigenesis. *Cell* 1990;**61**:759-67.
- Jass JR. Hyperplastic polyps of the colorectum—innocent or guilty? *Dis Colon Rectum* 2001;**44**:163-6.
- Hawkins NJ, Ward RL. Sporadic colorectal cancers with microsatellite instability and their possible origin in hyperplastic polyps and serrated adenomas. *J Natl Cancer Inst* 2001;**93**:1307-13.
- Nusko G, Mansmann U, Partzsch U, et al. Invasive carcinoma in colorectal adenomas: multivariate analysis of patient and adenoma characteristics. *Endoscopy* 1997;**29**:626-31.
- Longacre TA, Fenoglio-Preiser CM. Mixed hyperplastic adenomatous polyps/serrated adenomas. A distinct form of colorectal neoplasia. *Am J Surg Pathol* 1990;**14**:524-37.
- Cooper HS. In: Sternberg SS, ed. *Diagnostic surgical pathology*. NY: Raven Press, 1994.
- Burgesson RE, Chiquet M, Deutzmann R, et al. A new nomenclature for the laminins. *Matrix Biol* 1994;**14**:209-11.
- Engvall E, Wewer UM. Domains of laminin. *J Cell Biochem* 1996;**61**:493-501.
- Colognato H, Yurchenco PD. Form and function: the laminin family of heterotrimeric. *Dev Dyn* 2000;**218**:213-34.
- Ryan MC, Tizard R, VanDevanter DR, et al. Cloning of the LamA3 gene encoding the alpha 3 chain of the adhesive ligand epiligrin. Expression in wound repair. *J Biol Chem* 1994;**269**:22779-87.
- Gerecke DR, Wagman DW, Champlaud MF, et al. The complete primary structure for a novel laminin chain, the laminin B1k chain. *J Biol Chem* 1994;**269**:11073-80.
- Kallunki P, Sainio K, Eddy R, et al. A truncated laminin chain homologous to the B2 chain: structure, spatial expression, and chromosomal assignment. *J Cell Biol* 1992;**119**:679-93.
- Orian-Rousseau V, Aberdam D, Rousseau P, et al. Human colonic cancer cells synthesize and adhere to laminin-5. Their adhesion to laminin-5 involves multiple receptors among which is integrin alpha2beta1. *J Cell Sci* 1998;**111**(PT 14):1993-2004.
- Carter WG, Ryan MC, Gahr PJ. Epiligrin, a new cell adhesion ligand for integrin alpha 3 beta 1 in epithelial basement membranes. *Cell* 1991;**65**:599-610.
- Lohi J, Oivula J, Kivilaakso E, et al. Basement membrane laminin-5 is deposited in colorectal adenomas and carcinomas and serves as a ligand for alpha3beta1 integrin. *APMIS* 2000;**108**:161-72.
- Niessen CM, Hogervorst F, Jaspers LH, et al. The alpha 6 beta 4 integrin is a receptor for both laminin and kalinin. *Exp Cell Res* 1994;**211**:360-7.
- Spinardi L, Einheber S, Cullen T, et al. A recombinant tail-less integrin beta 4 subunit disrupts hemidesmosomes, but does not suppress alpha 6 beta 4-mediated cell adhesion to laminins. *J Cell Biol* 1995;**129**:473-87.
- Sordat I, Bosman FT, Dorta G, et al. Differential expression of laminin-5 subunits and integrin receptors in human colorectal neoplasia. *J Pathol* 1998;**185**:44-52.
- Baker SE, Hopkinson SB, Fitchmun M, et al. Laminin-5 and hemidesmosomes: role of the alpha 3 chain subunit in hemidesmosome stability and assembly. *J Cell Sci* 1996;**109**(PT 10):2509-20.
- Giannelli G, Falk-Marzillier J, Schiraldi O, et al. Induction of cell migration by matrix metalloprotease-2 cleavage of laminin-5. *Science* 1997;**277**:225-8.
- Koshikawa N, Giannelli G, Cirulli V, et al. Role of cell surface metalloprotease MT1-MMP in epithelial cell migration over laminin-5. *J Cell Biol* 2000;**148**:615-24.
- Pyke C, Romer J, Kallunki P, et al. The gamma 2 chain of kalinin/laminin 5 is preferentially expressed in invading malignant cells in human cancers. *Am J Pathol* 1994;**145**:782-91.
- Pyke C, Salo S, Ralfkiaer E, et al. Laminin-5 is a marker of invading cancer cells in some human carcinomas and is coexpressed with the receptor for urokinase plasminogen activator in budding cancer cells in colon adenocarcinomas. *Cancer Res* 1995;**55**:4132-9.
- Soini Y, Maatta M, Salo S, et al. Expression of the laminin gamma 2 chain in pancreatic adenocarcinoma. *J Pathol* 1996;**180**:290-4.
- Skyldberg B, Salo S, Eriksson E, et al. Laminin-5 as a marker of invasiveness in cervical lesions. *J Natl Cancer Inst* 1999;**91**:1882-7.
- Ono Y, Nakanishi Y, Ino Y, et al. Clinicopathologic significance of laminin-5 gamma2 chain expression in squamous cell carcinoma of the tongue: immunohistochemical analysis of 67 lesions. *Cancer* 1999;**85**:2315-21.
- Koshikawa N, Moriyama K, Takamura H, et al. Overexpression of laminin gamma2 chain monomer in invading gastric carcinoma cells. *Cancer Res* 1999;**59**:5596-601.
- Haas KM, Berndt A, Stiller KJ, et al. A comparative quantitative analysis of laminin-5 in the basement membrane of normal, hyperplastic, and malignant oral mucosa by confocal immunofluorescence imaging. *J Histochem Cytochem* 2001;**49**:1261-8.
- Lenander C, Habermann JK, Ost A, et al. Laminin-5 gamma2 chain expression correlates with unfavorable prognosis in colon carcinomas. *Anal Cell Pathol* 2001;**22**:201-9.
- Habermann J, Lenander C, Roblick UJ, et al. Ulcerative colitis and colorectal carcinoma: DNA-profile, laminin-5 gamma2 chain and cyclin A expression as early markers for risk assessment. *Scand J Gastroenterol* 2001;**36**:751-8.
- Hamilton SR, Vogelstein B, Kudo S, et al. Tumours of the colon and rectum. In: Hamilton SR, Aaltonen LA, eds. *World Health Organisation classification of tumours*. Lyon: IARC Press, 2000:103-44.
- Urbanski SJ, Kossakowska AE, Marcon N, et al. Mixed hyperplastic adenomatous polyps—an underdiagnosed entity. Report of a case of adenocarcinoma arising within a mixed hyperplastic adenomatous polyp. *Am J Surg Pathol* 1984;**8**:551-6.
- Salo S, Haakana H, Kontusaari S, et al. Laminin-5 promotes adhesion and migration of epithelial cells: identification of a migration-related element in the gamma2 chain gene (LAMC2) with activity in transgenic mice. *Matrix Biol* 1999;**18**:197-210.
- Sordat I, Rousseau P, Chaubert P, et al. Tumor cell budding and laminin-5 expression in colorectal carcinoma can be modulated by the tissue micro-environment. *Int J Cancer* 2000;**88**:708-17.
- Giannelli G, Antonaci S. Biological and clinical relevance of laminin-5 in cancer. *Clin Exp Metastasis* 2001;**18**:439-43.
- Iino H, Jass JR, Simms LA, et al. DNA microsatellite instability in hyperplastic polyps, serrated adenomas, and mixed polyps: a mild mutator pathway for colorectal cancer? *J Clin Pathol* 1999;**52**:5-9.
- Hamilton SR. Origin of colorectal cancers in hyperplastic polyps and serrated adenomas: another truism bites the dust. *J Natl Cancer Inst* 2001;**93**:1282-3.



Laminin 5 γ 2 chain expression: a marker of early invasiveness in colorectal adenomas

C Lenander, U J Roblick, J K Habermann, et al.

Mol Path 2003 56: 342-346

doi: 10.1136/mp.56.6.342

Updated information and services can be found at:

<http://mp.bmj.com/content/56/6/342.full.html>

These include:

References

This article cites 39 articles, 14 of which can be accessed free at:

<http://mp.bmj.com/content/56/6/342.full.html#ref-list-1>

Email alerting service

Receive free email alerts when new articles cite this article. Sign up in the box at the top right corner of the online article.

Notes

To request permissions go to:

<http://group.bmj.com/group/rights-licensing/permissions>

To order reprints go to:

<http://journals.bmj.com/cgi/reprintform>

To subscribe to BMJ go to:

<http://group.bmj.com/subscribe/>